

Case Report

A Case of Mature Cystic Teratoma Mimicking a Pericardial Cyst

Elcin Ersoz Kose,¹ Mustafa Vayvada,¹ Mustafa Akyil,¹ Deniz Gurer,¹ Yelda Tezel,² Cagatay Tezel¹

¹Department of Thoracic Surgery, Health Sciences University, Sureyyapasa Training and Research Hospital, Istanbul, Turkey

²Department of Chest Disease, Health Sciences University, Haydarpasa Numune Training and Research Hospital, Istanbul, Turkey

Abstract

The majority of mediastinal germ cell tumors are teratomas. Placement in the anterior mediastinum of the thorax is common, and placement in other compartments of the mediastinum and parenchyma can be observed as well. The main aim of treatment of mature and immature teratomas is complete removal of the mass without complications. Excision provides cure and its prognosis is very good. In this case, we aimed to discuss the case of a 22-year-old patient with anterior mediastinal involvement, which was first thought to be an anterior cystic pericardial cyst and was determined to be a mature cystic teratoma during resection.

Keywords: Anterior mediastinum, mature cystic teratoma, mediastinal mass

Cystic teratoma is a rare germ cell tumor, usually found in the anterior mediastinum. Benign teratomas comprise three primordial layers: ectoderm (skin and hair), mesoderm (bone, oil, and muscle), and endoderm (respiratory epithelium and gastrointestinal tract).^[1] Mature cystic teratomas are usually observed in the second and third decades of life. Cystic and solid components tend to grow slowly. They are incidentally detected during radiological studies and usually do not have any symptoms. Curative treatment is surgical excision.^[2]

Case Report

A 22-year-old female patient presented to our clinic with a complaint of chest pain. On chest X-ray, the right mid-zone oval smooth limited opacity was detected (Fig. 1a). Thorax computed tomography (CT) showed a restricted cystic lesion in the anterior mediastinum and right atrium junction (Fig. 1b). Magnetic resonance imaging revealed cystic lesions measuring 5×7×8.5 cm in size, extending from the caudal to paracardiac area of the right upper anterior mediastinum, and nodular areas containing fat signal in the

right lateral side of the cyst (Fig. 2). A paracardiac cyst was considered as the preliminary diagnosis, and videothoracoscopic removal of the cyst was planned. However, during the surgery, the lesion was found to be very solid and could not be removed from the port incision; therefore, anterior thoracotomy was performed. The mass was dissected from the pericardium and lung (Fig. 3a) and was removed by total excision (Fig. 3b). Histology concluded a diagnosis of a cystic teratoma which was 8×7×3.5 cm in size, the outer face of which was uniformly covered, with hair on the inside, and the material texture of the putty consistency. No complications were observed in the postoperative period, and the patient was discharged on the 4th day after hospitalization.

Discussion

Teratomas are tumors of embryonic origin that contain structures derived from at least two of the three germ (endoderm, mesoderm, and ectoderm) leaf components. In total, 3%–7% of all germ cell tumors are extragonadal. The distribution of teratomas according to the frequency



of appearance is, in decreasing order, as follows: ovaries, testis, anterior mediastinum, retroperitoneum, presacral and coccygeal region, intracranial area, and neck. The most common site in adults is the anterior mediastinum.^[1-3] In our case, the cystic mass was located in the anterior mediastinum, cardiophrenic angle.

Teratomas are usually found in adolescent and young adults, similar to our case.^[4] They are mostly asymptomatic and incidentally detected; most of the symptomatic patients present with intrathoracic symptoms, such as cough, chest pain, and shortness of breath due to the pressure of the mass.^[1] Our patient also complained of chest pain for approximately 3 months. Hemoptysis, stridor, hoarseness,

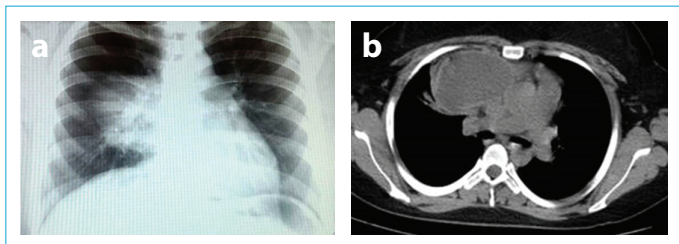


Figure 1. (a) A well-defined paracardiac cystic mass image on the mid-zone of the chest X-ray. (b) Paracardiac mass on thorax CT.

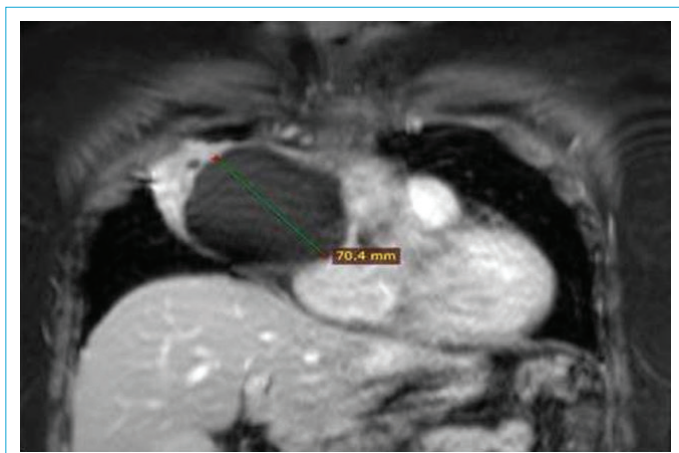


Figure 2. Paracardiac cystic mass (7 cm in diameter) on thorax MRI.

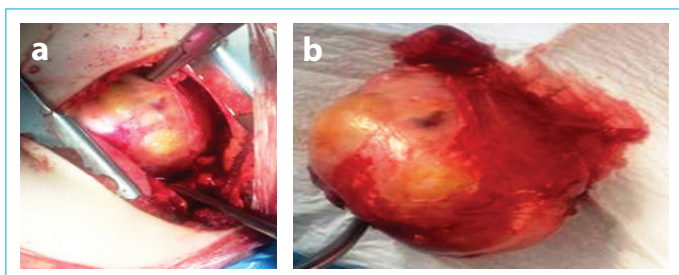


Figure 3. (a) Intrathoracic view of the mediastinal mass. (b) Macroscopic view after excision.

recurrent respiratory infections, Horner Syndrome, and Vena Cava Superior Syndrome may be observed, but are rare, depending on the complication of the mass. (3 If the lesion is associated with trachea or bronchus, sebaceous material and hair expectoration may occur. Pneumothorax, empyema, and cardiac tamponade may be observed if the lesion ruptures extending to the pleural and pericardial space.^[4] It may also be associated with recurrent hypoglycemic episodes, sometimes because of the presence of ectopic pancreatic tissue.^[5]

Teratomas are cystic and solid components and tend to grow slowly. Approximately 80% are benign, and most of them are cystic.^[6] They are incidentally detected on chest X-ray, which is usually performed for other reasons. They are seen as a well-defined mass on direct chest X-ray; sometimes calcifications or cavities within the tumor can also be seen. CT helps in identifying the content, uniformity, and size of the well-defined mass; a combination of fluid-filled cystic structures, fat, soft tissue, and calcification is observed in the contents of the mass. Magnetic resonance imaging is useful in determining the lesion's content and its relation with neighboring structures.^[1,2]

Invasive diagnostic methods, such as needle aspiration, mediastinoscopy, and mediastinotomy are used for cytologic and histological diagnosis of mediastinal masses. There are indications for videothoracoscopy or thoracotomy for diagnosis and/or treatment of cases that are not diagnosed by other methods or are diagnosed and operable.^[7]

Curative treatment of mediastinal teratomas is surgical excision, but if the location of the mass and the relationship of the mass with the surrounding tissues does not allow total excision, successful treatment may be achieved with subtotal resection.^[7] Radiotherapy or chemotherapy is not required because mediastinal teratomas are cured by resection.^[8] In our patient, no additional treatment was performed because the mass could be completely excised.

Complications that can be observed in teratomas are torsion, malignant degeneration, rupture, and infection. Malignant transformation is extremely rare and is observed in approximately 0.17%–2% cases.^[9] No complication was observed in our patient, and she was followed up for 10 months without any symptoms.

In conclusion, if the asymptomatic mass lesion radiologically detected in the mediastinum is of a semisolid-cystic nature, although they are rare, tumors of the teratoid origin should be considered during differential diagnosis.

Disclosures

Informed Consent: Written informed consent was obtained from the patient who participated in this study.

Peer-review: Externally peer-reviewed.

Conflict of Interest: None declared.

Authorship contributions: Concept – E.E.K., C.T.; Design – E.E.K.; Supervision – C.T.; Materials – E.E.K.; Data collection &/or processing – E.E.K.; Analysis and/or interpretation – E.E.K.; Literature search – E.E.K.; Writing – E.E.K.; Critical review – E.E.K., C.T.

References

1. Shields T. Benign germ cell tumors of the mediastinum. In: Allen MS, Trastek VF, Pairolero PC, editors. *General Thoracic Surgery*. Philadelphia: Williams & Wilkins; 2009. p. 2390–5.
2. Moran CA, Suster S. Primary germ cell tumors of the mediastinum: I. Analysis of 322 cases with special emphasis on teratomatous lesions and a proposal for histopathologic classification and clinical staging. *Cancer* 1997;80:681–90. [\[CrossRef\]](#)
3. Wright CD. Germ Cell Tumors of The Mediastinum. In: Pearson FG, Cooper JD, Deslauries J, Ginsberg RJ, Hiebert CA, Patterson CA, Urschel HC, editors. *Thoracic Surgery*. 2nd ed. Philadelphia: Churchill Livingstone; 2002. p. 1711–9.
4. Chaganti RS, Houldsworth J. Genetics and biology of adult human male germ cell tumors. *Cancer Res* 2000;60:1475–82.
5. Cansever L, Kocatürk İC, Aydoğmuş Ü, Ürer N, Yılmazbayhan D, Bedirhan MD. Mature cystic teratoma, ectopic mediastinal pancreas: a case report. *Türk Göğüs Kalp Damar Cer Derg* 2010;18:71–3.
6. Güngör A. Mediasten. *Klinik Cerrahi Onkoloji*. Ünal A, editor. Ankara: Özkan Matbaacılık; 1997. p. 448–9.
7. Gökçe M, Saydam Ö, Kılıçgün A, Karapolat S, Gezer S. Mediastinal Mas–ses; the Analysis of 28 Cases in the Western Black Sea Region. *J Clin Anal Med* 2013;4:93–5. [\[CrossRef\]](#)
8. Yüksel M, Çelikel T, Ceyhan B, Çelik M, Zonüzi F. Primer mediastinal germ hücreli tümörler: 4 vaka nedeniyle. *Turk J Oncol* 1995;10:64–7.
9. Toktaş O. Mature Cystic Teratoma of the Anterior Cervical Region: Case Report. *CausaPedia* 2014;3:745–9.