

Case Report

Successful Treatment of Rhinocerebral Mucormycosis with Combination of Liposomal Amphotericin B and Caspofungin (LAmB-C): An Anecdotal Clinical Experience that Deserves Further Investigations

Hakan Kocoglu¹, Yildiz Okuturlar¹, Zahide Mine Yazici², Mehmet Hursitoglu¹, Ozlem Harmankaya¹
Bahar Pehlivan¹, Abdalbaki Kumbasar¹

¹Department of Internal Medicine, Bakırköy Dr. Sadi Konuk Education and Research Hospital, Istanbul, Turkey

²Department of Otorhinolaryngology, Bakırköy Dr. Sadi Konuk Education and Research Hospital, Istanbul, Turkey

Abstract

Despite surgical interventions and antifungal therapies, the overall mortality of rhino-cerebral mucormycosis remains high. New therapeutic approaches are required in this field. Herein, we presented the first case report of a diabetic patient with rhinocerebral mucormycosis who was successfully treated with surgical intervention and a combination of liposomal amphotericin B (LAmB) (5mg/kg/day) and caspofungin (70mg followed by 50mg daily). We reported an anecdotal clinical experience of successful outcome in established mucormycosis likely to be attributable to the combination of LAmB and caspofungin. The combination of LAmB plus Caspofungin is presumably the best optimal combination therapy for rhino-orbital-cerebral mucormycosis. The potential role of caspofungin in the combination therapy against mucormycosis deserves further investigations.

Keywords: Caspofungin, echinocandins, liposomal amphotericin B, mucormycosis

Mucormycosis is a rare and potentially life-threatening infection that occurs most frequently in patients with diabetic ketoacidosis or in immunocompromised patients.^[1,2] Despite surgical interventions and antifungal therapies, the overall mortality still remains $\geq 50\%$, especially in the presence of cranial nervous system extension. Due to the increasing incidence of mucormycosis and its high mortality rate, novel treatment approaches are needed.^[2,3]

Mucor, *Rhizopus*, and *Lichtheimia* (formerly *Absidia*) species are the most common causes of mucormycosis, accounting for 70–80% of all cases. Moreover, *Cunninghamella*, *Rhizomucor*, *Actinomucor*, *Apophysomyces*, *Cokeromyces*, *Saksena*, and *Syncephalastrum* species are responsible

for less than 1–5% of the reported cases of mucormycosis.^[4] Amphotericin B (AmB) and its lipid formulation are antifungal agents approved for treating invasive mucormycosis. Previous studies have reported that echinocandins, such as caspofungin, have had no activity in vitro against *Mucorales*.^[5-7] Therefore, it was known that echinocandins are ineffective in treating mucormycosis; however, a recent study performed on diabetic mouse models reported that *Rhizopus oryzae*, the most common pathogen causing mucormycosis, expresses the target enzyme for echinocandins, which can be inhibited by caspofungin.^[8] Moreover, in this study, a synergistic effect between caspofungin and ABLC has been observed.^[9]

Address for correspondence: Hakan Kocoglu, MD, Department of Internal Medicine, Bakırköy Dr. Sadi Konuk Education and Research Hospital, Istanbul, Turkey
Phone: +90 506 380 92 15 **E-mail:** dr.hakankocoglu@gmail.com

Submitted Date: September 16, 2017 **Accepted Date:** September 17, 2017 **Available Online Date:** September 24, 2017

©Copyright 2017 by Eurasian Journal of Medicine and Oncology - Available online at www.ejmo.org



Due to its rarity, it is difficult to conduct randomized controlled trials related to treatment approaches for invasive mucormycosis. Hence, successful treatment cases, especially which could change the initial treatment approach, should be presented. Therefore, we aimed to present the first case report of a patient with rhinocerebral mucormycosis who was successfully treated with surgical intervention and a combination of liposomal amphotericin B (LAmB) and caspofungin.

Case Report

A 51-year-old woman was admitted to the emergency room with the complaints of fever and malaise. The patient's medical history included poorly controlled diabetes mellitus type 2.

Biochemical investigations during admission included blood count, serum electrolytes, urea, kreatinin, glucose, complete urine test, arterial blood gas analysis, and C-reactive protein. Results of the studies were consistent with the diagnosis of diabetic ketoacidosis due to an infection of unknown origin. Full body physical examination revealed an ulcer of approximately 2.5 cm diameter on the right side of the palate, near the second upper molar tooth and a lymphadenopathy of approximately 4 cm diameter behind the right submandibular gland (Fig. 1). The results of remaining physical examination were normal.

On the first day of hospitalization, her speech became dysarthric; she revealed right-sided hemifacioedema, and double vision due to inward gaze of the right eye because of paralysis of the VI cranial nerve. Furthermore, she had impaired vertical eye movements and outward gaze of the left eye. Neurological examination was also performed and the muscle strengths of left upper and lower extremities

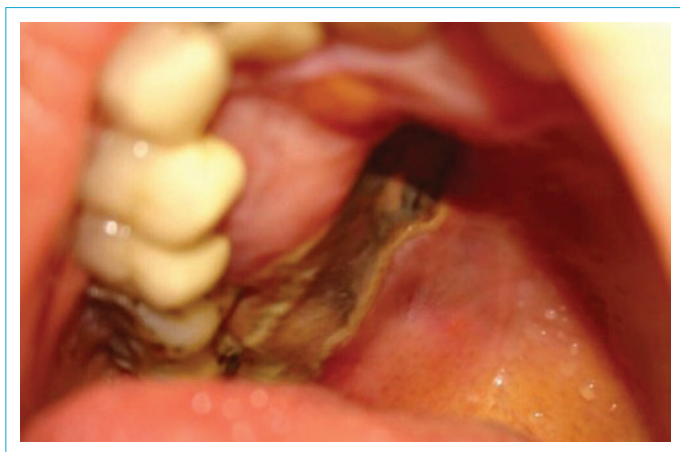

Figure 1. Physical examination revealed an ulcer of approximately 2.5 cm diameter on the right side of the palate, near the second upper molar tooth.

were graded as 1/5 and 3/5, respectively, and the Babinski response revealed extensor on the left and flexor on the right.

Computerized tomography revealed destructive lesion on the right side of palate invading the right maxillary sinus (Fig. 2). Further imaging with magnetic resonance imaging indicated thrombosis in cavernous sinus, in right internal carotid artery, and infiltrates at ethmoid and maxillary sinuses. A biopsy was done from the palatal ulcer and Gram and KOH staining were performed on the biopsy material. KOH preparation revealed broad, ribbon like, aseptate hyphae when examined under a fluorescence microscope. Mucormycosis was diagnosed based on these findings.

A combination of liposomal amphotericin B (AmBisome®; 5 mg/kg/day) and caspofungin (Cancidas®; 70 mg followed by 50 mg daily) and piperacillin tazobactam (Tazocin®; 4.5 g thrice a day) were initiated. After 3 days, she was subjected to surgery and right partial maxillectomy; the lesions in the ethmoid and maxillary sinuses were removed. Following surgery, all treatments were continued. During hospitalization, she was also subjected to more effective blood glucose management. She presented gradual improvement and was discharged free of any infection.

Discussion

A recent retrospective review of 120 cases of mucormycosis in patients with hematological malignancies has reported that treatment with LAmB was associated with significantly higher survival rate, compared to AmB (67% vs. 39%).^[10] A rabbit model study reported that ABLC had lower CNS penetration, compared with LAmB or AmB^[11], which makes it a less desirable option for treating mucormycosis with CNS extension.^[1] A study has reported that ABLC had low-

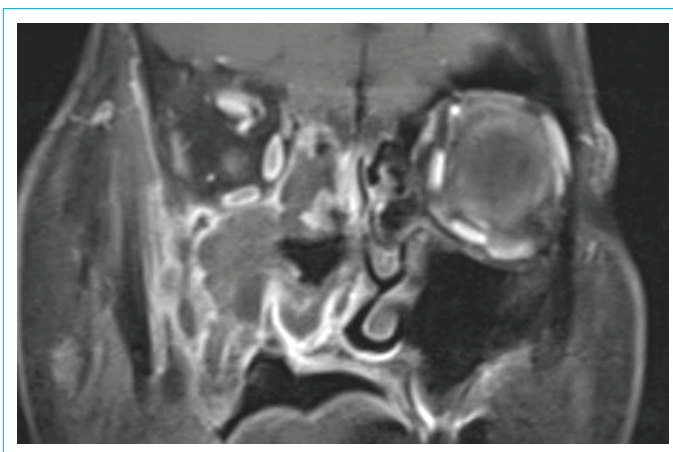


Figure 2. Turbo-spin echo (TSE) with fat saturation (FS) for coronal T1-weighted MRI of the cranium revealed heterogeneous contrast-enhancing lesion in the right maxillary and ethmoidal sinuses.

er success rates than either AmB or LAmB in patients with rhino-orbital-cerebral mucormycosis. Moreover, multivariate modeling of this study revealed that only combination therapy (ABLC or LAmB plus caspofungin) was significantly associated with the improved survival.^[12] Würthwein et al. also reported that the pharmacokinetics of caspofungin was not altered by the coadministration of LAMB and vice versa.^[13] In another study, neither caspofungin nor ABLC therapy alone mediated any survival benefit, whereas their combination significantly improved survival (50% survival for the combination vs. 0% for placebo, caspofungin alone, or ABLC alone).^[9] Even though only synergistic effect of caspofungin and ABLC has been proven, using this combination in mucormycosis infections without CNS involvement seems more logical. Based on these data, a combination of LAmB plus Caspofungin seems the best optimal combination therapy for rhino-orbital-cerebral mucormycosis. To the best of our knowledge, this is the second case of a diabetic patient with rhinocerebral mucormycosis who was successfully treated by a combination of LAmB and caspofungin.

Disclosures

Informed Consent: Written informed consent was obtained from the patient who participated in this study.

Peer-review: Externally peer-reviewed.

Financial Disclosure: The authors declared that this study has received no financial support.

Conflict of Interest: The authors declare no conflict of interest.

Authorship contributions: Concept – H.K., Y.O.; Design – H.K., Y.O., Z.M.Y., M.H.; Supervision – Y.O., M.H., O.H., A.K.; Materials – Z.M.Y., B.P.; Data collection &/or processing – H.K., Y.O., Z.M.Y., M.H., O.H., B.P., A.K.; Analysis and/or interpretation – H.K., Y.O., Z.M.Y., M.H., O.H., B.P., A.K.; Literature search – H.K.; Writing – H.K., Y.O., Z.M.Y., M.H., B.P.; Critical review – Y.O., Z.M.Y., M.H., O.H., A.K.

References

- Spellberg B, Edwards J Jr, Ibrahim A. Novel perspectives on mucormycosis: pathophysiology, presentation, and management. *Clin Microbiol Rev* 2005;18:556–69.
- Roden MM, Zaoutis TE, Buchanan WL, Knudsen TA, Sarkisova TA, Schaufele RL, et al. Epidemiology and outcome of zygomycosis: a review of 929 reported cases. *Clin Infect Dis* 2005;41:634–53.
- Marr KA, Carter RA, Crippa F, Wald A, Corey L. Epidemiology and outcome of mould infections in hematopoietic stem cell transplant recipients. *Clin Infect Dis* 2002;34:909–17.
- Gomes MZ, Lewis RE, Kontoyiannis DP. Mucormycosis caused by unusual mucormycetes, non-Rhizopus, -Mucor, and -Lichtheimia species. *Clin Microbiol Rev* 2011;24:411–45.
- Espinel-Ingroff A. Comparison of In vitro activities of the new triazole SCH56592 and the echinocandins MK-0991 (L-743,872) and LY303366 against opportunistic filamentous and dimorphic fungi and yeasts. *J Clin Microbiol* 1998;36:2950–6.
- Pfaller MA, Marco F, Messer SA, Jones RN. In vitro activity of two echinocandin derivatives, LY303366 and MK-0991 (L-743,792), against clinical isolates of *Aspergillus*, *Fusarium*, *Rhizopus*, and other filamentous fungi. *Diagn Microbiol Infect Dis* 1998;30:251–5.
- Del Poeta M, Schell WA, Perfect JR. In vitro antifungal activity of pneumocandin L-743,872 against a variety of clinically important molds. *Antimicrob Agents Chemother* 1997;41:1835–6.
- Ibrahim AS, Bowman JC, Avanesian V, Brown K, Spellberg B, Edwards JE Jr, et al. Caspofungin inhibits *Rhizopus oryzae* 1,3-beta-D-glucan synthase, lowers burden in brain measured by quantitative PCR, and improves survival at a low but not a high dose during murine disseminated zygomycosis. *Antimicrob Agents Chemother* 2005;49:721–7.
- Spellberg B, Fu Y, Edwards JE Jr, Ibrahim AS. Combination therapy with amphotericin B lipid complex and caspofungin acetate of disseminated zygomycosis in diabetic ketoacidotic mice. *Antimicrob Agents Chemother* 2005;49:830–2.
- Gleissner B, Schilling A, Anagnostopoulos I, Siehl I, Thiel E. Improved outcome of zygomycosis in patients with hematological diseases? *Leuk Lymphoma* 2004;45:1351–60.
- Groll AH, Giri N, Petraitis V, Petraitiene R, Candelario M, Bacher JS, et al. Comparative efficacy and distribution of lipid formulations of amphotericin B in experimental *Candida albicans* infection of the central nervous system. *J Infect Dis* 2000;182:274–82.
- Reed C, Bryant R, Ibrahim AS, Edwards J Jr, Filler SG, Goldberg R, et al. Combination polyene-caspofungin treatment of rhino-orbital-cerebral mucormycosis. *Clin Infect Dis* 2008;47:364–71.
- Würthwein G, Young C, Lanvers-Kaminsky C, Hempel G, Trame MN, Schwerdtfeger R, et al. Population pharmacokinetics of liposomal amphotericin B and caspofungin in allogeneic hematopoietic stem cell recipients. *Antimicrob Agents Chemother* 2012;56:536–43.