

Case Report

Subacute Thyroiditis During Peginterferon Alfa Therapy for Chronic Hepatitis Delta

Fatih Kuzu,¹ Elif Neslihan Akdemir²

¹Department of Internal Medicine, Division of Endocrinology and Metabolism, Dumlupınar University Kütahya Evliya Çelebi Training and Research Hospital, Kütahya, Turkey

²Department of Nuclear Medicine, Dumlupınar University Kütahya Evliya Çelebi Training and Research Hospital, Kütahya, Turkey

Abstract

Subacute thyroiditis is a nonsuppurative inflammation of the thyroid gland. Although there are case reports on the formation of subacute thyroiditis in patients with hepatitis C virus (HCV) and hepatitis B virus (HBV) receiving interferon treatment, there are no reports regarding the development of subacute thyroiditis in patients with hepatitis D virus (HDV) receiving interferon treatment. Here, we present the case of a patient with subacute thyroiditis receiving peginterferon alfa-2a for chronic HDV and to our knowledge this is the first report in the literature.

Keywords: Hepatitis D virus (HDV), interferon, subacute thyroiditis

The relation between interferon treatment and thyroid diseases was first reported in 1985 in patients receiving interferon treatment for breast cancer.^[1] Numerous studies researching thyroid diseases developing in patients with hepatitis B virus (HBV) and hepatitis C virus (HCV) during interferon treatment have been published since then.^[2] Subacute thyroiditis is a nonsuppurative inflammation of the thyroid gland. Case reports regarding the formation of subacute thyroiditis in patients with HCV and HBV receiving interferon treatment have been submitted.^[3]

There is no effective drug for acute HDV treatment, whereas for chronic HDV treatment, only interferons can be used. It has been reported in many studies that interferon rather makes viral suppression and suppresses liver in some patients, but this recovery has not been permanent in most patients.^[4]

Currently, there is rare data on the basic thyroid status of patients with chronic HDV who can cope with interferon

treatment. There is no published data on the development of subacute thyroiditis in chronic HDV cases receiving interferon therapy. We present the case of a patient with subacute thyroiditis receiving peginterferon alfa-2a for chronic HDV.

Case Report

A 41-year-old female patient complaining of right upper quadrant pain underwent laboratory examination and ultrasonographic imaging 10 months ago, which revealed increased liver function tests and diffuse coarseness in liver parenchymal echogenicity, respectively.

The patient was subsequently diagnosed with HDV with an HDV-RNA level of 58.620 copy/ml. Following the liver trucut biopsy, a mild chronic active hepatitis pathology was observed, and fibrous expansion and short fibrous septa were observed in most of the portal areas. Peginterferon alfa-2a treatment was initiated subsequent to the di-

Address for correspondence: Fatih Kuzu, MD. Department of Internal Medicine, Division of Endocrinology and Metabolism, Dumlupınar University Kütahya Evliya Çelebi Training and Research Hospital, Kütahya, Turkey

Phone: +90 530 826 62 04 **E-mail:** drfkuzu@hotmail.com

Submitted Date: December 05, 2017 **Accepted Date:** December 20, 2017 **Available Online Date:** May 07, 2018

©Copyright 2018 by Eurasian Journal of Medicine and Oncology - Available online at www.ejmo.org



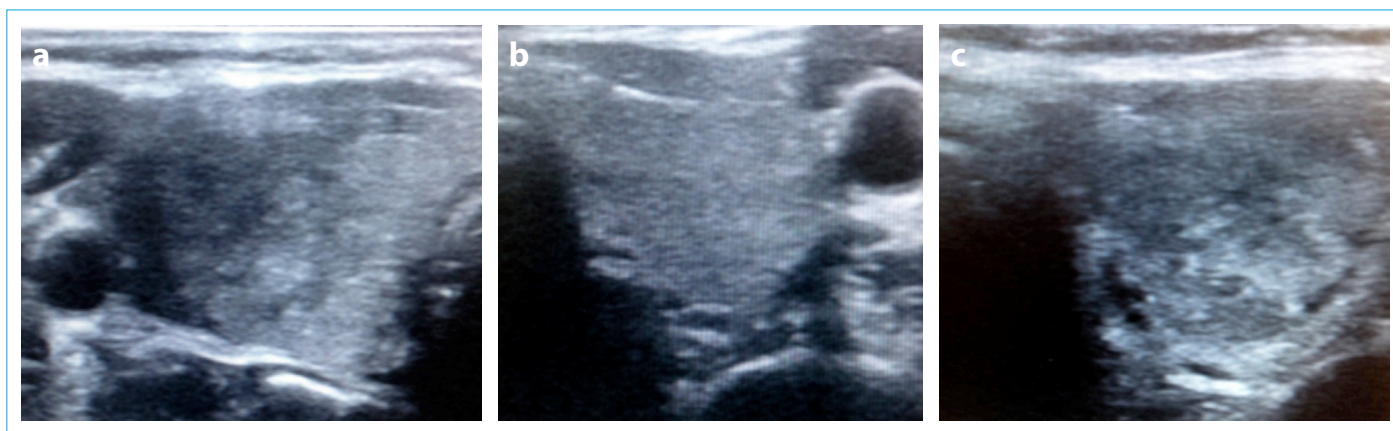


Figure 1 (a-c). (a) Transverse grayscale sonogram showing poorly defined patchy hypoechoic lesions in the right thyroid lobe (at admission). (b) Transverse grayscale sonogram showing normal thyroid parenchyma in the left thyroid lobe (at admission). (c) Transverse grayscale sonogram showing poorly defined patchy hypoechoic lesions in the left thyroid lobe (16 days after admission).

agnosis of chronic HDV.

The patient was diagnosed with thyroid dysfunction at the 3rd month of peginterferon alfa-2a treatment and thus referred to our endocrinology clinic. The patient presented to our clinic with a complaint of severely increasing pain in the anterior neck surface 2 weeks ago. The pain increased with swallowing and neck movements. The patient also complained of dizziness, anorexia, and palpitation. On physical examination, her weight was 72 kg and height was 164 cm. The arterial blood pressure was 125/70 mmHg and pulse was 96/min and rhythmic.

Acute-phase reactant as C-reactive protein (CRP) and erythrocyte sedimentation rate (ESR) was moderately increased. In her thyroid function tests, when the serum thyroid-stimulating hormone (TSH) was suppressed, her free T3 and free T4 levels were in the normal range (Table 1). Her right thyroid lobe was diffusely enlarged on palpation. Significant tenderness and pain were detected in the right lobe, whereas the same were not detected in the left lobe.

Table 1. Acute-phase reactant, thyroid hormones, and antithyroid antibodies during the clinical course.

Time	At admission	16 days after admission	36 days after admission
CRP (<5 mg/L)	5.9	4	1.8
ESR (0-20 mm/h)	25	39	7
TSH (0.38-5.3 mIU/m)	0.09	0.12	3.61
Free T4 (0.61-1.12 ng/dl)	1.10	1.36	0.54
Free T3 (2.5-3.9 pg/ml)	3.41	3.85	2.80
Anti TPO (0-9 IU/mL)		2	
Anti TG (0-3 IU/mL)		1	

CRP: C-reactive protein; ESR: erythrocyte sedimentation rate; TSH: thyroid-stimulating hormone; Anti-TPO: antithyroid peroxidase; Anti-TG: antithyroglobulin.

Patchy hypoechoic heterogeneities were detected in the right lateral thyroid lobe on ultrasonographic imaging (Fig. 1). The sonographic appearance of the left lobe was normal. There was significant suppression in the right lobe on scintigraphic imaging (Fig. 2).

Peginterferon alfa-2a treatment was continued, and a beta blocker and nonsteroidal anti-inflammatory were added to the treatment. The patient's complaints continued in her control after 16 days. Palpation, diffuse enlargement in thyroid gland lobes, pain, and tenderness were deter-

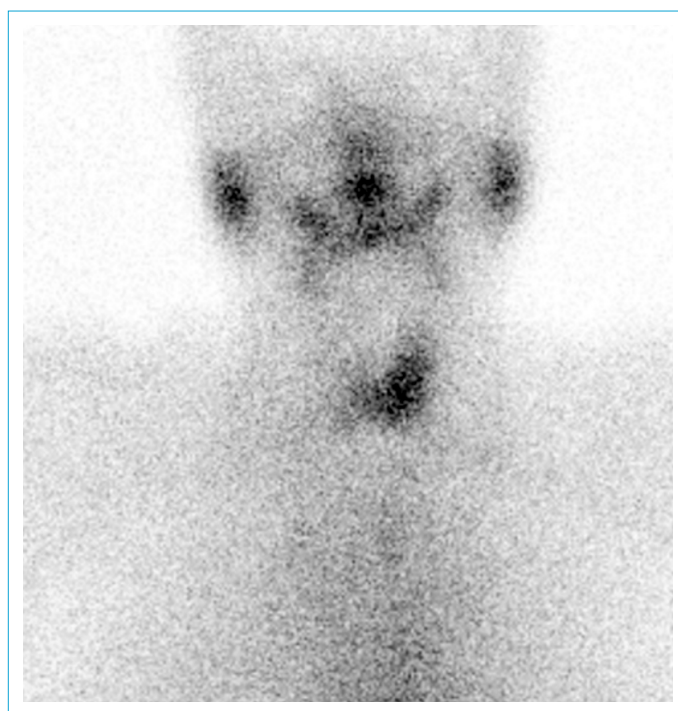


Figure 2. Scintigraphic imaging of thyroid with Tc pertechnetate (at admission); suppressed thyroid gland, evident on the right. The findings support the preliminary diagnosis of thyroiditis.

mined. ESR and free T4 levels values were higher compared with those during admission. Antithyroid antibodies were determined to be negative. Patchy hypoechoic heterogeneities were detected in both right and left lobes on sonographic evaluation. The peginterferon alfa-2a treatment was terminated on consultation with a gastroenterologist. Nonsteroidal anti-inflammatory treatment was continued. Pain and tenderness with palpation was not detected on neck examination in the patient's last control (36 days after admission). There were no complaints of fatigue, loss of appetite, and palpitation. The patient's acute-phase reactants were in the normal range. TSH and free T3 were normalized and free T4 levels were reduced in thyroid function tests (Table 1).

First, nonsteroidal anti-inflammatory and beta blocker therapy was initiated. Next, peginterferon alfa 2-a treatment was also stopped, and the patient recovered. The patient was followed up for l-thyroxine requirement later.

Discussion

Interferon is a critical cytokine in immune responses to infectious agents. As such, it is thought that it will trigger autoimmunity when it is given at pharmacological doses. Interferon-induced inflammation may cause thyroiditis in the autoimmune process, while its direct toxic effect on thyroid which is unrelated immunity mechanisms may lead to thyroid gland function defects in some patients and can trigger for thyroiditis.^[5, 6] Tomer et al.^[7] have proposed the classification of interferon-induced thyroiditis (IIT) as autoimmune IIT and nonautoimmune IIT. Autoimmune IIT includes Graves' disease, Hashimoto's thyroiditis, and thyroid autoantibodies with no clinical disease, while nonautoimmune IIT includes destructive thyroid and nonautoimmune hypothyroidism.

Thyroid dysfunction can occur at any time following treatment with interferon. Abnormalities can be diagnosed from an early time, such as 4 weeks from the start of the antiviral treatment until the end 23rd month. Diagnosis is made based on thyroid function tests and autoantibody levels. There is no need to interrupt the interferon treatment. Thyroid abnormalities in more than 50% of patients are subsequently recovered 6 months after treatment. Permanent hypothyroidism is more likely to develop in patients with thyroid autoantibodies before starting interferon treatment, and follow-up is more important in these patients.^[2, 6, 7] Scanning of autoantibodies is recommended before, during, and after interferon treatment, and patients should be informed of the risks of thyroid dysfunction.^[5, 6] Our case was a female patient with chronic HDV infection who was treated with interferon treatment. This patient

had no history of upper respiratory tract infection and hyperthyroidism occurred in the third month of treatment and it was cured by itself within 20 days after discontinuation of the drug, suggesting that interferon was the actual cause of thyroid dysfunction. Autoimmune thyroid disease was excluded because of the negative detection of thyroid autoantibodies. Specific imaging in sonography and suppressed detection of the thyroid gland by scintigraphy supports the diagnosis of subacute thyroiditis.

Silent destructive thyroiditis is diagnosed based on low radioactive iodine uptake after thyrotoxicosis and negative TSH receptor antibody results. No treatment is indicated if the patient is asymptomatic during the thyrotoxic phase. However, if symptoms develop, β -blockers might be needed. In severe cases, discontinuation of interferon treatment may be required, and it must be re-started only after the thyroid functions return to normal again. The time of destructive thyroiditis is variable between a few weeks and a month, and hypothyroidism may occur after the follow-up.^[2, 7] Our patient was followed up by giving beta-blockers in addition to analgesic and anti-inflammatory due to hyperthyroidism symptoms during application. When our patient had more severe complaints during the next control on and involvement was seen in the right lobe in addition to the left lobe, an opinion of a gastroenterologist was taken and the interferon treatment was stopped. Corticosteroids generally are useful in subacute thyroiditis, and the use of them is not preferred in patients with acute and chronic hepatitis because they are contraindicated. The patient was followed up due to the risk of hypothyroidism and the need for l-thyroxine replacement.

A high correlation was found between HCV and thyroid autoimmunity in previous studies. These findings suggest that HCV and interferon treatment may have a synergistic role in the formation of thyroid disease. Interferon-induced antithyroid antibodies in addition to thyroid disease often reduce after the discontinuation of treatment. It is recommended to determine autoantibody positivity before interferon treatment, while routine control of antithyroid antibodies before interferon treatment is not recommended in patients with HBV because autoimmune thyroid is not common, especially in patients with no family history.^[2, 6, 7] Complaints such as fatigue, weight loss, and palpitation, which can be seen as side effects of interferon can also be confused with similar findings, which can be seen at the same time in the course of thyroid diseases. Therefore, close follow-up of thyroid hormones is important in patients receiving interferon treatment.

Thyroid disorders in patients with HDV are a neglected issue. Because there is limited information in manuals, there

are no recommendations regarding screening of thyroid for patients with HDV. Currently, there is rare information about the basic thyroid situation of patients with chronic HDV who can cope with interferon treatment.^[8-10] Suvak et al. have evaluated 127 patients with chronic HDV in their study. Hypothyroidism was detected in 4.7% of patients, but patients with hyperthyroidism were not detected.^[8] Although subacute thyroiditis is rarely seen in HCV and HBV occurrences in the way of case notifications have been published.^[3] There is no publication related to the development of subacute thyroiditis in patients with chronic HDV using interferon. Our patient is the first case in the literature. It is thought that subacute thyroiditis may occur in interferon treatment not only in patients with HCV or HBV but also in those with HDV.

Disclosures

Informed consent: Written informed consent was obtained from the patient for the publication of the case report and the accompanying images.

Peer-review: Externally peer-reviewed.

Conflict of Interest: None declared.

Authorship contributions: Concept – F.K.; Design – F.K.; Supervision – F.K.; Materials – F.K., E.N.A.; Data collection &/or processing – F.K., E.N.A.; Analysis and/or interpretation – F.K., E.N.A.; Literature search – F.K.; Writing – F.K.; Critical review – F.K.

References

1. Fentiman IS, Thomas BS, Balkwill FR, Rubens RD, Hayward JL. Primary hypothyroidism associated with interferon therapy of breast cancer. *Lancet* 1985;1:1166. [\[CrossRef\]](#)
2. Menconi F, Hasham A, Tomer Y. Environmental triggers of thyroiditis: hepatitis C and interferon- α . *J Endocrinol Invest* 2011;34:78–84. [\[CrossRef\]](#)
3. Paran  R, Cruz M, Lyra L, Cruz T. Subacute thyroiditis during treatment with combination therapy (interferon plus ribavirin) for hepatitis C virus. *J Viral Hepat* 2000;7:393–5. [\[CrossRef\]](#)
4. Abbas Z, Khan MA, Salih M, Jafri W. Interferon alpha for chronic hepatitis D. *Cochrane Database Syst Rev* 2011:CD006002.
5. Deutsch M, Dourakis S, Manesis EK, Gioustozi A, Hess G, Horsch A, et al. Thyroid abnormalities in chronic viral hepatitis and their relationship to interferon alfa therapy. *Hepatology* 1997;26:206–10. [\[CrossRef\]](#)
6. Tomer Y, Menconi F. Hepatitis C and interferon induced thyroiditis. *Best Pract Res Clin Endocrinol Metab* 2009;23:703–12.
7. Tomer Y, Blackard JT, Akeno N. Interferon alpha treatment and thyroid dysfunction. *Endocrinol Metab Clin North Am* 2007;36:1051–66. [\[CrossRef\]](#)
8. Suvak B, Dulger AC, Ayka  MC, Gonullu H, Gonullu E. Delta hepatitis-related thyroid disease: a unique phenomenon. *Prz Gastroenterol* 2015;10:169–72. [\[CrossRef\]](#)
9. Rizzetto M, Smedile A. Pegylated interferon therapy of chronic hepatitis D: in need of revision. *Hepatology* 2015;61:1109–11.
10. Hughes SA, Wedemeyer H, Harrison PM. Hepatitis delta virus. *Lancet* 2011;378:73–85. [\[CrossRef\]](#)