

MULTIPL ADENOLIPOMAS OF THE BREAST

Sağol Ö¹ , Pabuçcuoğlu¹, Özen E¹, Özkal S¹.

Department of Pathology¹ , School of Medicine, Dokuz Eylül University, İzmir, Turkey

Adenolipomas or hamartomas of the breast are uncommon benign mammary lesions which have been seldom encountered in the radiological, surgical and pathological literature. The incidence of adenolipoma is uncertain and the etiology remains obscure (1).

Histologic appearance of adenolipomas of the breast has been defined as well circumscribed nodules or masses composed of varying amounts of fibrous tissue, fat and glandular elements. Adenolipomas are unilateral and generally solitary (1,2).

Here we report an unusual case of two distinct adenolipomas in one breast of a 43 years old woman and review the relevant literature.

Case Report:

A 43 year old woman who was diagnosed to have T3N2Mx invasive ductal carcinoma has underwent a right modified radical mastectomy. A month later following the operation, she was found to have two distinct masses on the lower-outer quadrant of her left breast.

On macroscopic examination of the excisional biopsy material, two encapsulated soft well-defined round lesions measuring 3x3x1,5 and 2x2x1,5 cm's with glistening surface, surrounded by a thin capsule, resembling a lipoma were seen. The cut surfaces of the lesions were yellow and mottled by grayish white areas.

Microscopically, both of the lesions were encapsulated and composed of adipous tissue with interspersed islands

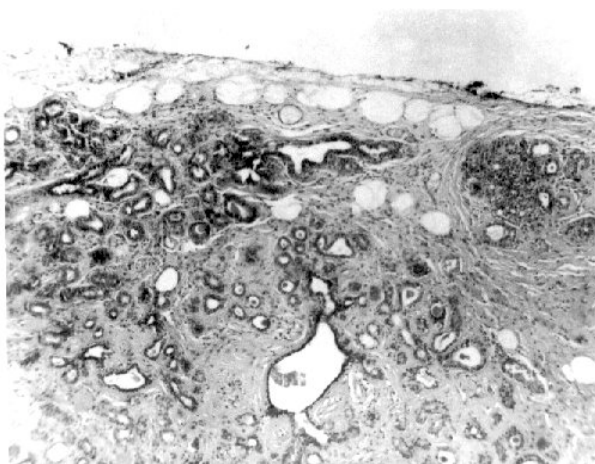


Figure 1: Mammary lobules embedded in fat tissue surrounded by a pseudocapsule (H&E, 40X)

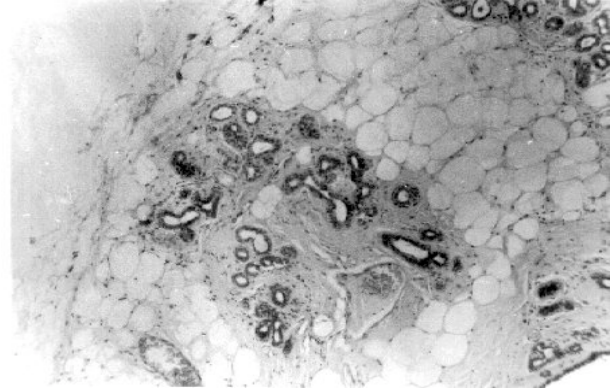


Figure 2: Slightly increased acini under the pseudocapsule of the adenolipoma (H&E, 100X)

of breast stroma showing mild fibrosis, occasional lactiferous ducts and slightly increased acini of the mammary lobules (Fig.1 and 2). The histopathological diagnosis was an "adenolipoma".

Discussion:

The terms adenolipoma, fibroadenolipoma, mastoma or mammary hamartoma have all been applied to probable identical lesions with varying amounts of benign epithelial elements, fibrous and adipous tissue. The spectrum of appearances seen in these lesions no doubt accounts for the variable terminology which has been applied to them. The appropriateness of the term mammary hamartoma has been questioned, one point being that it is not congenital and the other that it can contain heterologous elements such as cartilage and smooth muscle (2,3). Lesions that contain a significant amount of smooth muscle within the stroma have been called "muscular hamartomas" (2). In our cases no heterologous elements could be observed.

Hamartomas have been reported in patient aged 15-88 years. But they are mostly seen in women in their 4. and 5. decades (4). So far no case has been reported in a male (2). Hageman and Ostberg considered the condition to be secondary to lactation but in most series as well as in our case, no relation has been found with pregnancy or lactation (1).

Mammary hamartomas can present with clinically palpable masses or can be incidentally diagnosed during mammographic examinations as in our case. The masses may enlarge the breast, and show no adherence to skin and muscle. The size of the lesions ranges from 1 to 13

cm in diameter in reported cases. As they grow they can cause marked asymmetry of the breast. A lesion weighing 2953 gr was reported in the literature(2). Hamartomas are unilateral and generally solitary. Our case is interesting in that the lesions were multiple.

Macroscopically, adenolipomas are described as partially or completely encapsulated, with a smooth glistening surface often having a disc like or lentiform shape. Its cut surface is yellow and mottled by grayish white areas. There may be cystic areas (3). In our case two discrete masses with the typical macroscopic features of this entity were observed. On the cut surface, gray white areas representing mammary tissue were embedded in the lipomatous tissue. The macroscopic appearance of these lesions is important when making the diagnosis of mammary hamartoma as there is such a spectrum of changes on histologic examination that if a smooth outline and well-demarcated nature of the lesion is not noted on gross examination the diagnosis can easily be missed (2).

Microscopically, the lesion is composed of lactiferous ducts, mammary glands, connective and fatty tissue surrounded by a pseudocapsule, embedded in the adipose tissue simulating fibrocystic disease. No calcification is seen (4). As the microscopic features of hamartomas are similar to those of other related benign lesions of the breast, diagnosis may be difficult by histopathological examination alone; and in addition knowledge of radiological, surgical and clinical findings may be required (4). Fibroadenoma, lipoma and cystosarcoma phylloides must be differentiated from adenolipoma. The fibrous stroma of the fibroadenoma is usually more cellular. Besides, adipose tissue which is the major component of the hamartomas is infrequent in fibroadenoma and cystosarcoma phylloides.

It is generally agreed that adenolipomas are benign lesions but a few cases containing lobular carcinoma in situ were reported (5). Although the masses were found in

a patient with a history breast cancer, we did not find co-existing malignancy in this case.

The well-known radiological appearance of this entity is a well-demarcated mass with radiologically visible fat usually seen at the periphery but only few cases show this typical radiologic appearance. Ultrasound has a minimal role in the diagnosis of the breast hamartomas in view of their wide sonographic variability (1).

Mammary hamartomas can be treated by simple excision. It has been suggested that, when these lesions contain radiographically visible fat, the correct diagnosis may be made on mammography and surgical excision can be avoided. But as the clinical and radiological findings may not be specific, the lesions should be excised like other masses found in the breast.

References

1. Evers K, Yeh T, Trougin RH: Mammary hamartomas-the importance of radiologic-pathologic correlation. *Breast Dis* 5:35-43, 1992.
2. Fisher HJ, Hanby AM, Robinson L, Millis RR: Mammary hamartoma-a review of 35 cases. *Histopathology* 20(2):99-106, 1992.
3. Jones MW, Norris HJ, Wargots ES: Hamartoma of the breast. *Surg Gynecol Obstet* 173(1):54-6, 1991.
4. Altermatt HJ, Gebbers JO, Laissue JA: Multiple hamartomas of the breast. *Appl Pathol* 7(2): 145-8, 1989.
5. Coyne J, Hobbs FM, Boggis C, Harland R: Lobular carcinoma in a mammary hamartoma. *J Clin Pathol* 45(10):936-7, 1992.

Correspondence:

Özgül Sağol, M.D.

Department of Pathology

Dokuz Eylül University, School of Medicine

Incirtaltı, 35340 Izmir, Turkey