

Use of Contractubex® (Allantoin, Heparin, Extractum Cepae) to Prevent Scar Formation in The Rabbits to Which Primary Closure has been Applied After Urethrotomy

Kemal Ayengin^{1*}, Nizamettin Kılıç²

¹Van Yüzüncü Yıl University, Medical School, Department of Pediatric Surgery, Van, Turkey

²Uludağ University, Medical School, Departments of Pediatric Surgery and Pediatric Urology, Bursa, Turkey

ABSTRACT

The scar tissue occurring in operating area after the repair of hypospadias which is one of the common congenital anomalies of male children has part in formation of post-operative complications. Many surgical techniques and materials have been used to reduce complications. The purpose of this study is to research the effects of contractubex® (allantoin, heparin, extractum cepae [AHEC]) gel on development of scar in the area repaired after urethrotomy.

In the study, 45 male White New Zealand rabbits were used. The rabbits were divided into three groups randomly.

Group 1(K): The group to which urethrotomy and primary closure were applied

Group 2(A): The group to which urethrotomy, primary closure + 15-day AHEC were applied

Group 3(B): The group to which urethrotomy, primary closure + 30-day AHEC were applied

Urethras of the rabbits in the groups were calibrated with angiocath (24 Fr) once a day for 30 days. Along with calibration, AHEC was applied to the urethras of the rabbits in 2nd group for 15 days and urethras of the rabbits in the 3rd group for 30 days. To evaluate scar tissue, macroscopic and histopathological evaluations were carried out.

Although inflammation was much more in the groups to which AHEC was applied, fibrosis was determined to be less.

It is thought that the application of AHEC may be effective in reducing scar formation after operation.

Key Words: Hypospadias, Allantoin, Heparin, Extractum Cepae

Introduction

Hypospadias is the anomaly occurring due to partial development of anterior urethra. Urethral meatus can be opened anywhere on ventral side of the penis from just under glans to perineum (1). Hypospadias is seen in 1 in 300 male children on average (2,3). 60-65%, 20-30%, 10-15% of the cases are distal-located, mid-penile-located and proximal-located, respectively. In etiology, mother's using progesterone-like or androgen-like drugs during her pregnancy, advanced maternal age, in vitro fertilization babies, premature and monozygotic twins may be effective (5,6). However, the most important etiologic factor is thought to be androgen insufficiency. Androgen insufficiency is caused by faults in hypothalamic-pituitary-gonadal axis (lack of hCG), production of defective testicular and placental androgen, testosterone's not being able to be converted into

dihydrotestosterone due to 5 α -reductase enzyme deficiency, or insufficiency of androgen receptors in penis (6,7). After hypospadias surgeries, complications such as bleeding, hematoma, wound infection, wound dehiscence, necrosis on penile shaft skin, urinary tract infection and urinary retention can be seen in the early period, on the other hand, in the late period, such complications as urethrocutaneous fistula, meatal stenosis, recurrent and permanent chordee, urethral stricture, balanitis xerotica obliterans, urethrocele and urethral diverticulum can be seen (8,9).

The most frequent complication is urethrocutaneous fistula with the frequency of 10-15%. It is followed by diverticulum and stricture respectively. Obstruction of distal part of new urethra may cause tissue ischemia, strangulation on skin, tension on suture line, oedema on wound site, post operative infection, wound dehiscence,

*Corresponding Author: Kemal Ayengin, Van Yüzüncü Yıl University, Medical School, Department of Pediatric Surgery 65080, Van, Turkey
E-mail: kemalagengin@hotmail.com, Phone: +90 (432) 215 04 74/+90 (531) 302 23 33, Fax: +90 (432) 216 75 19

development of urethrocutaneous fistula after hypospadias surgery (10). Rates of complications vary depending upon seriousness of hypospadias cases, age of patient, experience of surgeon, whether there are enough tissues or not and the previous unsuccessful attempts (8). With choice of appropriate procedure, complications can be minimized with performing an application carefully on tissues, use of optical magnification, choosing good stents and absorbable sutures.

Extractum cepae is obtained from allium cepae. It shows antiphlogistic and antiallergic effect by inhibiting release of inflammation mediators. Sulphur peptides and carbohydrates (glucose, fructose) in its content provide cellular regeneration. They have anti-inflammatory and antiproliferative characteristics with flavanoids. Also, they contain vitamin A, B₁, B₂, B₆, C, cobalt, iron and trace elements. Vitamin A has epithelium protective effect. Extractum cepae inhibits growth of different originated fibroblasts, especially keloidal fibroblasts and has bactericidal effect. These features stimulates primary wound healing and prevents nonphysiological scar formation (11).

Allantoin is the last product of purine metabolism on animal and plant tissues. It not only stimulates cellular proliferation but also helps growth of healthy cells. It has the characteristics of stimulating epithelisation and providing formation of physiological scar and elastic surface. It accelerates wound healing and increases water binding capacity of tissue. It is keratolytic and has additive effect on penetration. It relieves itch accompanying generally scars (12).

When applied locally, heparin has inhibitor effect on fibroblast proliferation. It increases tissue hydration as well as reducing induration and irritation. Moreover, it reduces fibrin formation by influencing coagulation cascade and activates plasminogen activator. Thus, it stimulates fibrinolysis by increasing effect of plasminogen. Based on fibroblast growth factor, it accelerates wound healing (13,14).

It has been determined that AHEC causes inhibition on human fibroblast cultures (scar, keloid) depending upon its antiproliferative effect, reduces synthesis of collagen and proteoglycans and prevents polymerization of collagen (15-19).

The study has been planned for the purpose of researching histopathological changes which primary suture, primary suture + use of AHEC for 15 days, primary suture + use of AHEC for 30 days form in urethra in preventing formation of

scar tissue after urethrotomy formed in rabbit model.

Material and Method

The study was carried out in application laboratories of department of Pathology, Experimental Animal Raising and Research Centre (DHYAM), by receiving approval from Animal Experiments Local Ethics Committee (Approval Date: 23.02.2010, Decision No: 2010-02/5). In the study, totally 45 male white New Zealand rabbits, weighing 1400-2000 grams, were used in such a way that there would be 15 in each group. The rabbits were divided into three groups randomly:

Group 1(K): The group to which urethrotomy, primary closure was applied

Group 2(A): The group to which urethrotomy, primary closure + AHEC once for 15 days were applied

Group 3(B): The group to which urethrotomy, primary closure + AHEC once for 30 days were applied

Each gram of AHEC contains: 100 mg extractum cepae, 10mg allantoin and 50 IU heparin (Image 1A). For anaesthesia, 2% xylazine hydrochloride at dose of 8 mg/kg (ROMPUN®; Bayer Healthcare, Leverkusen, Germany) and ketamine hydrochloride at dose of 100 mg/kg (KETALAR®; Pfizer, USA) were applied into muscle. The rabbits were laid on application table in supine position (Image-1B). Operative field was cleaned using 10% povidone iodine (Batticon®; Adeka, Samsun, Turkey) solution and was covered in a sterile way. Urethra was catheterized with 6 Fr feeding (Image-1C). 2 cm-urethrotomy was carried out to ventral of penis vertically (Image -1D and E).

Following bleeding control, incision line was repaired twice with continuous sutures by using 7-0 polydioxanone suture (PDS II, ETHICON, Johnson and Johnson) (Image -1F and G). After operation, the feeding in urethra was taken out and the rabbits were taken into their cage.

Follow-up and Care of Subjects: The rabbits to which surgery was applied were taken into cages in groups. Group number and study date were written on each cage. All rabbits were fed with standard rabbit feed and were given water. The needs of rabbits for care and feeding were met by officials of DHYAM during operating time. Urethras of the rabbits in all groups were calibrated with 24gauge (G) angiocath once a day

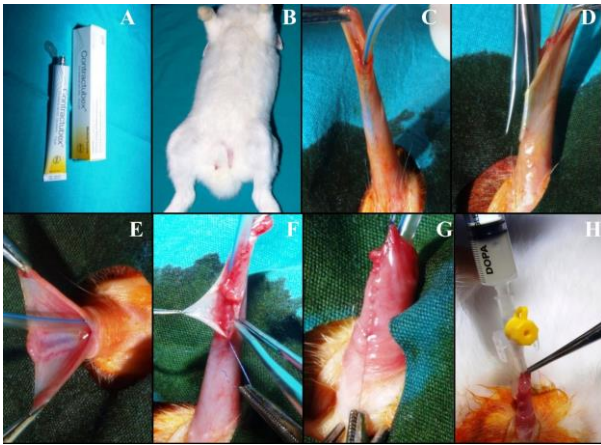

Image 1. Extractum Cepae- Allantoin- Heparin (Contractubex®) Gel (A), Rabbits were laid on application table in supine position (B), Catheterisation of Urethra with feeding (C), Performing urethrotomy (D), After urethrotomy (E), Condition in which mucosal repair was completed and second layer repair began (F), Condition in which two-layered repair was completed with continuous sutures (G) and Calibration of urethra of rabbit with angiocath and application of AHEC (H)

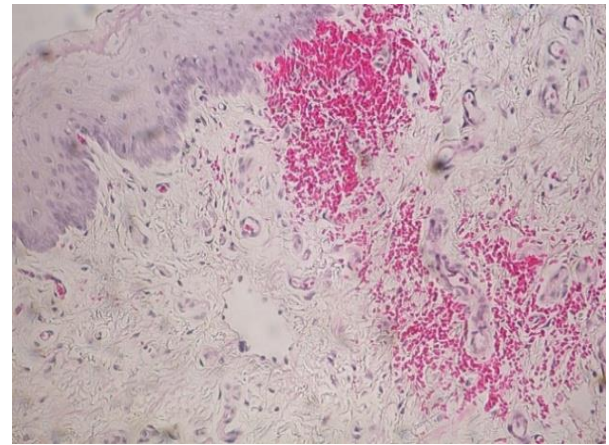


Image-2. Appearance of hyperaemia areas in group K with HE staining

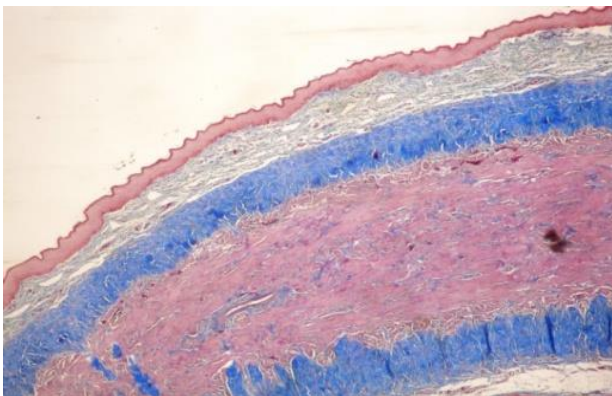


Image 3. Group K, fibrosis- less, MT staining (4x10 magnification)

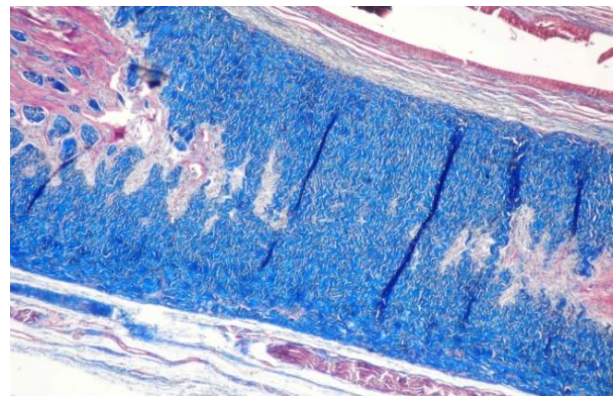


Image 4. Group B, fibrosis-more (blues areas), MT staining (4x10 magnification)

for 30 days. Along with calibration, 1cc AHEC was applied to urethras of the rabbits in the 2nd group once a day for 15 days and to urethras of those in the 3rd group once a day for 30 days (Image -1H).

Urinary diversion was not applied to any rabbits. In the end of 30 days, penectomy was done in a way that it would include the processing area in penis by sacrificing the rabbits with high dose of thiopental sodium (Pentothal, İ.E İlaç San. İstanbul, Turkey). Group names were written on each of three jars including 10% formalin. Penectomy materials were put into the jars to which they belonged, and they were sent to histopathological evaluation.

Macroscopic Evaluation: Operation areas were evaluated every day in terms of development of necrosis, fistula and hyperaemia. The rabbits were

followed closely in early days after operation in order to determine development of vesical globe and, when necessary, to give medical attention.

Histopathological Evaluation: Fixation of the taken samples was provided by being kept in 10%-formalin. 4-micron-sections were prepared in a way that they would include urethra, to which incision did not extend, in addition to operation area. The sections were evaluated histopathologically by being stained with haematoxylin-eosin (HE) and masson-trichrome (MT). In the evaluation, histopathological scoring system that Ayyildiz et. al. developed was used. In this scoring, a point was given to such parameters as lack of inflammation, lack of necrosis, lack of hyperaemia, lack of foreign reaction, lack of fistula, presence of neovascularisation, intraluminal and extraluminal epithelial integrity.

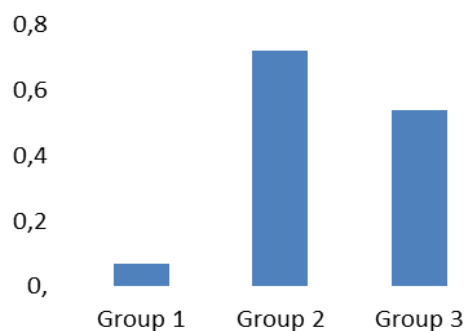


Fig. 1. Figureal presentation of rates of inflammation determined in groups

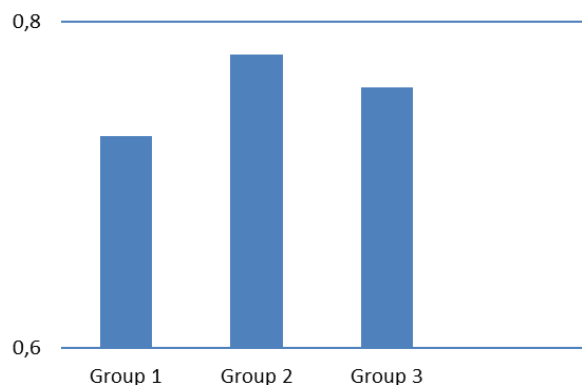


Fig. 2. Figureal presentation of rates of intraluminal epithelium integrity determined in groups

Fibrosis rating was carried out by modifying Ayyildiz et. al.'s study (21). In fibrosis evaluation, lack of fibrosis, mild fibrosis, moderate fibrosis and severe fibrosis were graded as 3, 2, 1, 0 respectively. All preperates were evaluated as blind. Increasing of bleeding flowing into tissue as a result of arteriolar dilatation was evaluated as hyperaemia, similarly, fibroblast proliferation and increase of collagen were evaluated as fibrosis. Infiltration of neutrophil and lymphocyte formed definition of inflammation and necrosis in epithelium and other tissues formed the definition of necrosis.

Statistical Evaluation: Analyses of the study were carried out through SPSS 13.0 (Chicago, IL) program. Each one of histopathological parameters was expressed with frequency, and chi-square test was used for comparisons among groups. In the study, total score values obtained from histopathological parameters were given as an absolute value. The numerical data given in the graphs represent the presence/absence rate. $P < 0.05$ was accepted as statistically significant in the study.

Results

During study, 2 of the rabbits in group 1 and 1 of the rabbits in group 2 were lost. Thus, the study

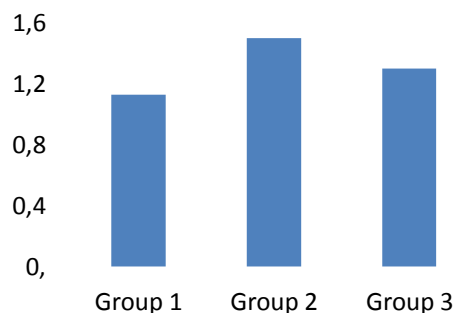


Fig. 3. Distribution of fibrosis rates determined in the rabbits according to groups

was completed with 42 rabbits (n_{group1} : 15, n_{group2} : 14, n_{group3} : 13). In the macroscopic evaluation of operation area, hyperaemia, oedema and infection were determined in three rabbits in group 3 and one rabbit in group 2. After operation, all rabbits urinated, and vesical globe did not develop in any rabbit; similarly, fistula and necrosis were not seen.

All preperates were evaluated under light microscope after being stained with HE and MT and their photographs were taken. Along with presence of neovascularisation and intraluminal and extraluminal epithelium integrity, Lack of hyperaemia, inflammation, fibrosis, necrosis, fistula and foreign reaction were accepted as healing criteria²¹ (Table-1,2,3). The data obtained as a result of evaluation of preperates belonging to the rabbits in the group-1, to which only primary closure was applied, with light microscopy were tabularised in Table-1.

The data obtained as a result of evaluation of preperates belonging to the rabbits in the group-A, to which AHEC was applied for 15 days in addition to primary closure, with light microscopy were tabularised in Table-2. The data obtained as a result of evaluation of preperates belonging to the rabbits in the group-A, to which AHEC was applied for 30 days after primary closure, with light microscopy were collected in Table-3. The least inflammation was observed in group K in histopathological evaluation and this group was followed by group B and group A respectively (Figure-1). P value for inflammation was 0,001 and there was significant difference between groups. Hyperaemia was observed in some rabbits in group K and p value was calculated as 0,055, so it was not statistically significant (Image-2). Neovascularisation was denser in group A. P value calculated as statistically 0,001 was significant. Although intraluminal epithelium integrity was determined higher in group A, it was high in all groups (Figure-2). P value of intraluminal epithelium integrity was determined as 0,944. This

Table 1. Histopathological data in preperates belonging to the rabbits in group K

Histopathological Parameters	K ₁	K ₂	K ₃	K ₄	K ₅	K ₆	K ₇	K ₈	K ₉	K ₁₀	K ₁₁	K ₁₂	K ₁₃	K ₁₄	K ₁₅
Lack of inflammation	1	1	1	1	1	0	1	1	1	1	1	1	1	1	1
Lack of necrosis	1	1	1	1	1	1	1	1	1	1	1	1	1	1	1
Lack of hyperaemia	1	1	1	1	0	1	1	1	0	1	1	1	1	1	0
Lack of foreign reaction	1	1	1	1	1	1	1	1	1	1	1	1	1	1	1
Lack of fistula	1	1	1	1	1	1	1	1	1	1	1	1	1	1	1
Presence of neovascularisation	0	0	0	1	0	0	0	0	0	0	0	0	0	1	0
Intraluminal integrity of epithelium	1	1	1	1	0	0	0	0	1	1	1	1	1	1	1
Extraluminal integrity of epithelium	0	1	1	1	0	1	1	1	1	1	1	1	1	1	1
Fibrosis score	0	0	0	2	1	2	1	1	2	2	1	1	2	0	2
Total score	6	7	7	10	5	7	7	7	8	9	8	8	9	8	8

Table 2. Histopathological data in preperates belonging to the rabbits in group A

Histopathological Parameters	A ₁	A ₂	A ₃	A ₄	A ₅	A ₆	A ₇	A ₈	A ₉	A ₁₀	A ₁₁	A ₁₂	A ₁₃	A ₁₄
Lack of inflammation	0	0	0	0	1	0	0	0	1	0	1	1	0	0
Lack of necrosis	1	1	1	1	1	1	1	1	1	1	1	1	1	1
Lack of hyperaemia	1	1	1	1	1	1	1	1	1	1	1	1	1	1
Lack of foreign reaction	1	1	1	1	1	1	1	1	1	1	1	1	1	1
Lack of fistula	1	1	1	1	1	1	1	1	1	1	1	1	1	1
Presence of neovascularisation	1	1	1	0	1	1	0	1	1	1	0	1	1	0
Intraluminal integrity of epithelium	0	1	1	0	1	1	0	1	1	1	1	1	1	1
Extraluminal integrity of epithelium	1	0	0	0	0	1	1	1	1	0	1	1	0	0
Fibrosis score	2	2	2	2	1	1	1	2	1	0	2	1	2	2
Total score	8	8	8	6	8	8	6	9	9	6	9	9	8	7

value was not statistically significant. Extraluminal epithelium integrity was high in group B and K, however, it was lower in group A compared to the other two groups. P value for extraluminal epithelium integrity was calculated as 0,018 and was statistically significant. While fibrosis was dense in the rabbits of group K, it was determined less dense in group B and A respectively (Figure-3) (Image-3,4). P value for fibrosis was found as 0,405, which was not statistically significant. Foreign reaction, necrosis and fistula were not determined in the groups. Thus, for these parameters, statistical calculation was not made. We summarized all the chi-square analysis results in Table 4.

Hypospadias is common congenital genitourinary anomaly of male children. It is seen in 3-5 of 1000 male children born alive. There are more than 300 procedures identified for treatment, nevertheless,

insufficiencies in treatment and complications may occur²². Scar tissues occurring after hypospadias repair increase post-operative complications. In our study, effects of AHEC were researched to prevent scar formation after hypospadias surgery and to reduce complications occurring based on scar formation.

Contractubex is consisted of extractum cepae, heparin and allantoin. Extractum cepae is obtained allium cepae. It inhibits release of inflammation mediator and provides cellular regeneration. It inhibits growth of different originated fibroblasts, especially keloidal fibroblasts and it has bactericidal effect. These features stimulate primary wound healing and prevent nonphysiological scar formation (11). Allantoin is keratolytic, increases water binding capacity of tissue, accelerates epithelisation, provides physiological scar formation. It relieves itch

Table 3. Histopathological data in preparates belonging to the rabbits in group B

Histopathological Parameters	B ₁	B ₂	B ₃	B ₄	B ₅	B ₆	B ₇	B ₈	B ₉	B ₁₀	B ₁₁	B ₁₂	B ₁₃
Lack of inflammation	1	1	0	0	0	1	0	0	1	1	0	0	1
Lack of necrosis	1	1	1	1	1	1	1	1	1	1	1	1	1
Lack of hyperaemia	1	1	1	1	1	1	1	1	1	1	1	1	1
Lack of foreign reaction	1	1	1	1	1	1	1	1	1	1	1	1	1
Lack of fistula	1	1	1	1	1	1	1	1	1	1	1	1	1
Presence of neovascularisation	0	0	0	1	0	1	0	0	0	0	0	0	0
Intraluminal integrity of epithelium	1	1	0	0	0	1	1	1	1	1	1	1	1
Extraluminal integrity of epithelium	1	1	1	0	1	1	1	1	1	1	1	1	1
Fibrosis score	0	2	1	1	2	1	1	2	1	1	2	2	1
Total score	7	9	6	6	7	9	7	8	8	8	8	8	8

accompanying scars¹². Heparin inhibits fibroblast proliferation, increases tissue hydration, reduces induration and irritation. It reduces fibrin formation by influencing coagulation cascade and it stimulates fibrinolysis by activating plasminogen activator. Based on fibroblast growth factor, it accelerates wound healing (13,14). It has been determined that the combined effects of AHEC reduce inflammation, fibroblast proliferation and synthesis of collagen and proteoglycans in last stages of wound healing depending upon its antiproliferative effect, and prevent polymerization of collagen (15-19).

Efficiency of AHES was evaluated in preventing epidural fibrosis developed in the rats to which laminectomy was applied. In the treatment, it was determined that the number of fibroblast and fibrosis score were significantly lower in the groups in which AHEC was used (23). In our study, we detected the highest fibrosis values in the rabbits of group K that we did not apply AHEC. We determined lower and the lowest values in group A, which we applied AHEC 15 days, and in group B, which we applied AHEC for 30 days, respectively (Figure-3, Image-10,11). However, this was not statistically significant.

Dorsch et. al. found in the study they carried out on humans that extractum cepae inhibits inflammation (24). In our study, the least inflammation was observed in group K in histopathological evaluation, and this group was followed by group B and A respectively; these values were statistically significant (Figure-1). Inflammation develops in the first stage of wound healing, and its purpose is to sanitise the wound²⁵. Although the fact that inflammation was found lower in group B than in group A supports the study carried out by Hosnuter et. al., the reason

why it was found lower in group K is requiring proof.

The most frequent complication after hypospadias repair is urethrocutaneous fistula with rate of 10-15 % (8,26). Success of the technique used in the repair is indexed to rates of fistula development²⁷. Subcuticular continuous sutures was seen to be safer in preventing leakage of urine from incision line compared to the sutures put one by one^{26,27}. Fibrin glue which is used in spleen traumas, health surgery and some colon operations due to its tissue adhesive and haemostasis features was used by Diner et. al. for the purpose of strengthening vesicourethral anastomosis after radical prostatectomy (28). Also, it was used by Gopal et. al. with the purpose of reducing fistula formation after hypospadias surgery²⁹. Gopal et. al. carried out hypospadias repair with tubularized transverse preputial island flap. In one group, after they entirely covered suture line of neourethral tube, they brought dartos flap over it. The leakage which occurs between tissues on suture line and is not able to be determined microscopically may lead to early post operative oedema, and then, fistula formation. They stated that Post operative oedema reduced up to 50% in the group in which fibrin glue was used. Rates of fistula were determined as 10% in treatment group and 31% in control group. Fibrin glue causes wound healing with minimal fibrosis. In the group in which fibrin glue was used, rates of urethral stricture and meatal stenosis were determined to be lower²⁹. In our study, we repaired incision line, occurring after urethrotomy we applied to rabbits, with continuous sutures. We did not encounter with any local or systemic side effects based on use of AHEC. After operation, we did not observe necrosis and fistula in repair line in any of the groups.

Table 4. Chi-square analysis of all data

		Group 1	Group 2	Group 3	P value
		Count	Count	Count (percent)	
		(percent)	(percent)		
Inflammation	Presence	1 (6.7%)	10 (71.4 %)	7 (53.8 %)	0.001
	Absence	14 (93.3%)	4 (28.6%)	6 (46.2%)	
Necrosis	Presence	0 (0%)	0 (0%)	0 (0%)	ND
	Absence	15 (100%)	14 (100%)	13 (100%)	
Hyperemia	Presence	3 (20%)	0 (0%)	0 (0%)	0.055
	Absence	12 (80%)	14 (100%)	13 (100%)	
Fistula	Presence	0 (0%)	0 (0%)	0 (0%)	ND
	Absence	15 (100%)	14 (100%)	13 (100%)	
Neovascularization	Presence	2 (13.3%)	10 (71.4%)	2 (15.4%)	0.001
	Absence	13 (86.7%)	4 (28.6%)	11 (84.6%)	
Intraluminal integrity of epithelium	Presence	4 (26.7%)	3 (21.4%)	3 (23.1%)	0.944
	Absence	11 (73.3%)	11 (78.6%)	10 (76.9%)	
Extraluminal integrity of epithelium	Presence	13 (86.7%)	7 (50.0%)	12 (92.3%)	0.018
	Absence	2 (13.3%)	7 (50.0%)	1 (7.70%)	
Fibrosis score	Severe	4 (26.7%)	1 (7.10%)	1 (7.70%)	0.405
	Moderate	5 (33.3%)	5 (35.7%)	7 (53.8)	
	Mild	6 (40.0%)	8 (57.1%)	5 (38.5%)	
Foreign reaction	Presence	0 (0%)	0 (0%)	0 (0%)	ND
	Absence	15 (100%)	14 (100%)	13 (100%)	

ND: Not detected, Group 1: Group K, Group 2: Group A and Group 3: Group B

Etiology of formation of urethral stricture after hypospadias repair is very various. Type of the tissues used in treatment, surgical technique, age of patient, experience of surgeon, other post operative complications may contribute to stricture formation. Gargollo et. al. applied urethrotomy and dilatation or urethroplasty to the cases developing urethral stricture. In the group in which urethroplasty was applied in the treatment of distal strictures, success rate was found statistically significant compared to the group in which urethrotomy and dilatation were applied. Also, in proximal strictures, they got 63% success in the group to which urethrotomy and dilatation were applied and 67% success in the group to which urethroplasty was applied. Moreover, in recurrent strictures, they determined success rate in the group to which urethroplasty was applied to be much higher compared to the group to which urethrotomy and dilatation were applied³⁰. All the rabbits in our study urinated spontaneously in post operative period. Meatal and urethral stenoses were not encountered during urethral calibrations; vesical globe did not develop in any rabbits. And urinary diversion was not applied.

The amount of histamine increases in hypertrophic scar tissue and keloids. Excessive

collagen production occurs by fibroblasts as a reaction to histamine increase³¹. Being main compounds of extractum cepae, quercetin and kaempferol are antihistaminic and ant proliferative effective. Based on these effects, excessive collagen production by fibroblasts can be suppressed (31-33). Heparin reduces or stops inflammation depending on dose. It has been determined to reduce the pain along with inflammation and coagulation in burn treatment and to accelerate healing by regulating blood flow. It regulates blood flow by accelerating development of rich vascular granulation tissue and revascularisation. In the group A and group B in our study, there were more neovascularisation than in group K, which is compatible with literature. Yet, hyperaemia was denser in group K compared to group A and group B.

AHEC is used in medical treatment of keloids and hypertrophic scars occurring after wound healing. Extractum cepae and heparin in its compound have anti-inflammatory and anti proliferative effects. Based on these effects, AHEC reduces proliferation of fibroblast, depresses collagen synthesis and encourages physiological scar formation. In our study, development of fibrosis was higher in group K compared to group A and

B; however, inflammation was determined to be higher in group A and B than in group K, which is different from literature.

Willital et. al. applied AHEC once a day for a year to a group in the study they carried out on 45 young patients experiencing thoracic surgery. In the end of the study, they determined that type, size and colour of the scar got better and incidences of hypertrophic scar and keloid reduced³⁵. In another study in which the group to which contractubex was applied after minor dermatologic surgery was compared with the group to which treatment was not applied, it was stated that scar formation in treatment group was less³⁶. Bracka method which is two-staged technique is also used in proximal hypospadias repair. In this method, the more scar-free and flat-surfaced urethral plate, which is used in formation of new urethra in the second stage, is, the less possibility of development of complication after operation is. After the first stage of the repair performed with Bracka method, AHEC can be used to obtain flat-surfaced plate. To evaluate efficiency of these treatments, we examined urethras of the rabbits which we repaired primarily after urethrotomy by not applying any treatment in group K but by applying AHEC in group A and B.

As a result of our evaluations based on our study, inflammation was determined to be higher in the rabbits of group A and B than in the rabbits of group K. We attributed this condition to being recurrently calibrated of rabbit urethras in group A and B with angiocath during daily application of AHEC. We detected neovascularisation, which is a desirable situation in wound healing, as the most in group A and, respectively, in group B and K. This finding can be interpreted in a way that AHEC affects neovascularisation positively. Necrosis and fistula did not develop in the groups. The reason of that may depend on application of repair as two-layered with 7-0 PDS and recurrent sutures and being tension of the tissues in operation area after operation. Any local or systemic side effects were not encountered in the group in which AHEC was used, which can indicate that AHEC can be used safely. One of the most important criteria in determination of hypertrophic scar tissue is fibrosis density. Fibrosis seen as blue colour with MT staining in preparates was the densest in the rabbits in group K numerically even if it was not statistically significant. While expected to be less denser in the rabbits in group B than those in group A, fibrosis density's being less denser in the rabbits in group

A was not explained. To reveal this issue and get more accurate results, performing experimental studies in which ages and weights of the rabbits are the same and application of medicine is more standard is appropriate.

Consequently, when side effects happening in long-term treatments with drugs, especially corticosteroids, are taken into consideration, AHEC can be used in treatment of development of scar tissue in surgical wounds in children.

1. References

- Price R, Lambe G, Jones R. Two-stage hypospadias repair: audit in a district general hospital. *British journal of plastic surgery* 2003; 56: 752-758.
- Baskin LS, Ebberts MB. Hypospadias: anatomy, etiology, and technique. *Journal of pediatric surgery* 2006; 41: 463-472.
- Wilcox D, Snodgrass W. Long-term outcome following hypospadias repair. *World journal of urology* 2006; 24: 240-243.
- Alexander K, Leung WL, Robson. Hypospadias: an update. *Asian J Androl* 2007; 9: 16-22.
- Gallentine ML, Morey AF, Thompson IM, Jr. Hypospadias: a contemporary epidemiologic assessment. *Urology* 2001; 57: 788-790.
- Silver RI, Rodriguez R, Chang TS, Gearhart JP. In vitro fertilization is associated with an increased risk of hypospadias. *J Urol* 1999; 161: 1954-1957.
- Dolk H. Epidemiology of Hypospadias. In: Hadidi AT, Azmy AF (eds). *Hypospadias Surgery*. 1st edition. Berlin: Springer; Vol 1st edition. Berlin: Springer 2004; 51-57.
- Snyder CL, Evangelidis A, Hansen G, et al. Management of complications after hypospadias repair. *Urology* 2005; 65: 782-785.
- Nuininga JE, RP DEG, Verschuren R, Feitz WF. Long-term outcome of different types of 1-stage hypospadias repair. *J Urol* 2005; 174: 1544-1548.
- Sunay M, Dadalı M, Karabulut A, Emir L, Erol D. Our 23-year experience in urethrocutaneous fistulas developing after hypospadias surgery. *Urology* 2007; 69: 366-368.
- Draeos ZD. The ability of onion extract gel to improve the cosmetic appearance of postsurgical scars. *Journal of cosmetic dermatology* 2008; 7: 101-104.
- Stozkowska W, Raczyńska K. Efficiency and application safety of Cepan cream. Observation of a new indication. *Przegląd lekarski*. 2008; 65: 241-243.
- Arikan S, Adas G, Barut G, et al. An evaluation of low molecular weight heparin and hyperbaric oxygen treatment in the prevention of intra-abdominal adhesions and wound healing. *The American journal of surgery* 2005; 189: 155-160.

15. Saliba Jr MJ. Heparin in the treatment of burns: a review. *Burns* 2001; 27: 349-358.
16. Majewski S, Chadzynska M. Effects of heparin, allantoin and cepae extract on the proliferation of keloid fibroblasts and other cells in vitro. *Posterpräsentatio MS* 1988; 24-29.
17. Wiesmann P. Effect fo Contractubex, an anti-keloid medication, and its individual components on the synthesis and secretion of glycosaminoglycan, sulfated glycosaminoglycans and collagen in cultured skin fibroblasts. *Merz Forschungsbericht*. 1991.
18. Janicki S, Sznitowska M. Effect of ointments for treating scars and keloids on metabolism of collagen in scar and healthy skin. *European journal of pharmaceutics and biopharmaceutics* 1991; 37: 188-191.
19. Beuth J, Hunzelmann N, Van Leendert R, Basten R, Noehle M, Schneider B. Safety and efficacy of local administration of Contractubex® to hypertrophic scars in comparison to corticosteroid treatment. Results of a multicenter, comparative epidemiological cohort study in Germany. *In vivo* 2006; 20: 277-283.
20. Janicki S, Sznitowska M, Maceluch J, Jaśkowski J. Studies on the viscous-elastic properties of the skin in evaluating ointments to improve the elasticity of scars. *Przegląd dermatologiczny* 1988; 75: 352-357.
21. Koliadenko V, Stepanenko V, Bardov P. New approaches to the treatment and prophylaxis of the cicatrix formation. *Klinichna khirurgiia* 2001: 24-27.
22. Ayyildiz A, Çelebi B, Akgül KT, Nuhoglu B, Caydere M, Germiyanoglu C. A comparison of free skin graft, fascia lata, alloderm, bovine pericardium and primary repair in urethrocutaneous fistulas without diversion: an experimental study. *Pediatric surgery international* 2006; 22: 809-814.
23. Gill NA, Hameed A. Management of hypospadias cripples with two-staged Bracka's technique. *J Plast Reconstr Aesthet Surg* 2011; 64: 91-96.
24. Ozay R, Yavuz OY, Aktas A, et al. Effects of cepae extract, allantoin, and heparin mixture on developing and already formed epidural fibrosis in a rat laminectomy model. *Turk J Med Sci* 2016; 46: 1233-1239.
25. Dorsch W, Schneider E, Bayer T, Breu W, Wagner H. Anti-inflammatory effects of onions: inhibition of chemotaxis of human polymorphonuclear leukocytes by thiosulfonates and cepaenes. *Int Arch Allergy Appl Immunol* 1990; 92: 39-42.
26. Levine E, Cupp AS, Miyashiro L, Skinner MK. Role of transforming growth factor-alpha and the epidermal growth factor receptor in embryonic rat testis development. *Biol Reprod* 2000; 62: 477-490.
27. Sarhan OM, El-Hefnawy AS, Hafez AT, Elsherbiny MT, Dawaba ME, Ghali AM. Factors affecting outcome of tubularized incised plate (TIP) urethroplasty: single-center experience with 500 cases. *J Pediatr Urol* 2009; 5: 378-382.
28. Mohamed S, Mohamed N, Esmael T, Khaled S. A simple procedure for management of urethrocutaneous fistulas; post-hypospadias repair. *Afr J Paediatr Surg* 2010; 7: 124-128.
29. Diner EK, Patel SV, Kwart AM. Does fibrin sealant decrease immediate urinary leakage following radical retropubic prostatectomy? *J Urol* 2005; 173: 1147-1149.
30. Gopal SC, Gangopadhyay AN, Mohan TV, et al. Use of fibrin glue in preventing urethrocutaneous fistula after hypospadias repair. *J Pediatr Surg* 2008; 43: 1869-1872.
31. Gargollo PC, Cai AW, Borer JG, Retik AB. Management of recurrent urethral strictures after hypospadias repair: is there a role for repeat dilation or endoscopic incision? *J Pediatr Urol* 2011; 7: 34-38.
32. Tredget EE, Anzarut A. Effect of Mederma on hypertrophic scarring in the rabbit ear model by Alexandrina S. Saulis, MD, Jon H. Mogford, Ph.D., and Thomas A. Mustoe, MD - Discussion. *Plast Reconstr Surg* 2002; 110: 184-186.
33. Ho WS, Ying SY, Chan PC, Chan HH. Use of onion extract, heparin, allantoin gel in prevention of scarring in chinese patients having laser removal of tattoos: A prospective randomized controlled trial. *Dermatol Surg* 2006; 32: 891-896.
34. Willital GH, Heine H. Efficacy of Contractubex(R) Gel in the Treatment of Fresh Scars after Thoracic-Surgery in Children and Adolescents. *International Journal of Clinical Pharmacology Research* 1994; 14: 193-202.
35. Beuth J, Hunzelmann N, Van Leendert R, Basten R, Noehle M, Schneider B. Safety and efficacy of local administration of Contractubex (R) to hypertrophic scars in comparison to corticosteroid treatment. Results of a multicenter, comparative epidemiological cohort study in Germany. *In Vivo* 2006; 20: 277-283.
36. Willital G, Heine H. Efficacy of Contractubex gel in the treatment of fresh scars after thoracic surgery in children and adolescents. *International journal of clinical pharmacology research* 1994; 14: 193-202.
37. Prager W, Gauglitz GG. Effectiveness and Safety of an Overnight Patch Containing Allium cepa Extract and Allantoin for Post-Dermatologic Surgery Scars. *Aesthet Plast Surg* 2018; 42: 1144-1150.