

Treatment of Osteochondral Lesions of the Talus with Transmalleolar Open Mosaicplasty

Cihan Adanaş*, Sezai Özkan

Department of Orthopedics and Traumatology, Van Yüzüncü Yıl, Van, Turkey

ABSTRACT

To evaluate middle-term outcomes of patients that underwent open mosaicplasty due to osteochondral lesions of the talus causing chronic complaints.

The retrospective study included 23 patients that were diagnosed with a Grade III, IV, and V osteochondral lesion of the talus according to the Bristol classification system between January 2014 and December 2017. Pain assessment was performed using Visual Analog scale (VAS 1-10) and functional outcomes were assessed using the AOFAS (American Orthopedic Foot & Ankle Society) Ankle-Hindfoot Rating System. Additionally, a questionnaire was filled out by each patient both preoperatively and at 1 year postoperatively.

Mean AOFAS score was 55.652 preoperatively and was 88.913 postoperatively and a significant difference was found between the two scores ($p < 0.001$). Similarly, mean VAS score was 7.39 preoperatively and was 2.04 postoperatively and a significant difference was found between the two scores ($p < 0.001$).

Open mosaicplasty appears to be a useful technique for the treatment of cystic osteochondral lesions of the talar dome larger than 10 mm in diameter. The technique is also safe and effective and allows successful closure of the cartilaginous loss with hyaline cartilage.

Key Words: Mosaicplasty, talus, osteochondral lesion, transmalleolar osteotomy

Introduction

Osteochondral lesions of the talus often manifest with a pain and loss of joint motion in the ankle. Although these lesions are mostly attributed to trauma, their exact mechanism of formation remains unknown (1). The etiology of osteochondral lesions includes direct trauma, alignment abnormalities, hormone disorders, osteonecrosis, and recurrent microtrauma (2). Among these lesions, stage I-II lesions may heal spontaneously, whereas stage III-IV-V lesions may remain asymptomatic or may lead to ankle arthritis. The lesions are mostly seen in young individuals and the primary goal in the treatment of these lesions is to prevent the formation of arthritis at later ages (3).

Osteochondral lesions are mostly diagnosed by imaging techniques including conventional radiography, magnetic resonance imaging (MRI), and bone scintigraphy. Additionally, diagnostic arthroscopy can also be useful particularly in suspicious lesions (4). Chronic osteochondral lesions are mostly classified using the Bristol classification described by Hepple et al., which has been shown to be a highly efficient and effective MRI-based classification system (5). Conservative treatments of osteochondral lesions include modification of daily

life activities, rehabilitation support, intra-articular steroid injection, platelet-rich plasma injection, and bracing (6). On the other hand, common surgical procedures include osteochondral fixation, bone marrow stimulation (microfracture), articular cartilage repair (mosaicplasty, osteochondral allograft transplantation), autologous chondrocyte implantation, non-cell seeded scaffolds, and surface replacement arthroplasty (7-8). In osteochondral lesions, the choice of surgical technique depends on several factors including lesion size and location, activity level of the patient, and the severity of the symptoms.

In this study, we aimed to evaluate middle-term outcomes of patients that underwent open mosaicplasty due to osteochondral lesions of the talus causing chronic complaints.

Materials and Methods

The retrospective study included 23 patients that presented to Yuzuncu Yil University Medical School Orthopedics and Traumatology Department and were diagnosed with a Grade III, IV, and V osteochondral lesion of the talus according to the Bristol classification system between January 2014 and December 2017. This study was approved by local

*Corresponding Author: Cihan Adanaş, Department of Orthopaedic and Traumatology, Van Yuzuncu Yil University, Dursun Odabas Medical Center, Tuşba, Van

E-mail: cihanadanas@hotmail.com, Phone: +90 (553) 782 35 65

Received: 14.06.2019, Accepted: 23.09.2019

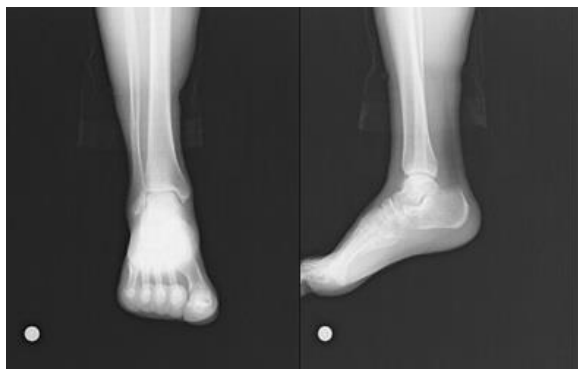


Fig. 1. Preoperative ankle anterior-posterior and lateral radiography

ethics committee (Ethics committee date and number: 10.05.2019/09-06).

Patients with an ankle arthritis, rheumatological and metabolic disorders, a history of surgery in the ankle, and patients aged over 45 years were excluded from the study.

The lesions were diagnosed by physical examination and MRI evaluation. The diagnosis was confirmed by diagnostic arthroscopy. Following the establishment of the diagnosis, mosaicplasty was concurrently performed with open surgery (Figure 1-2)

Surgical Technique: Under spinal or general anesthesia, a tourniquet was applied to the affected lower extremity and the site was cleaned. Diagnostic arthroscopy was then performed via anteromedial and anterolateral portals to obtain diagnostic information about the lesion. Following the arthroscopy, a medial or lateral ankle incision was made on the affected side for mosaicplasty. An oblique medial malleolar osteotomy was performed in a proximal-to-distal direction as described by Dijk et al. (9) (Figure 3). In laterally localized lesions, an oblique osteotomy was performed below the level of the syndesmosis by preserving the integrity of the extrinsic lateral ligaments. After complete exposure of the lesion site, lesion size was measured. Subsequently, the ipsilateral knee joint was accessed via a medial parapatellar incision. An appropriately sized osteochondral graft was harvested from the non-weight-bearing portion of the medial femoral condyle of the talus using an Osteochondral Autograft Transfer System (OATS) set. In the defect site in the talus, graft tunnels were drilled using the drill provided by the OATS set. The harvested grafts were placed in the tunnels as appropriate to the contours of the talus and then the ankle joint motion was assessed. After cleaning the surgical site, the medial malleolar osteotomy was fixed with tension-band wiring and the osteosynthesis of the lateral malleolar osteotomy was fixed with plate-screw system. The surgical site was closed appropriately.

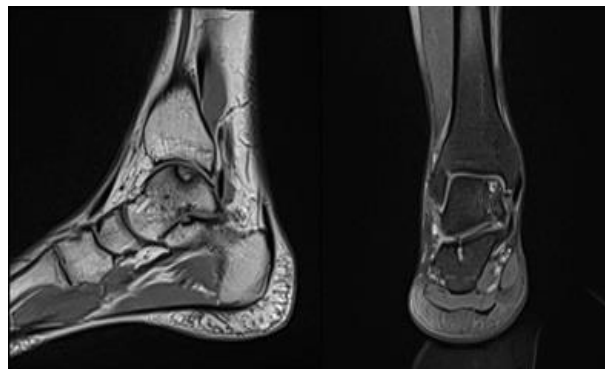


Fig. 2. Preoperative MR images of a patient with osteochondral defect in the talus

The operated extremity was placed in a short-leg splint for up to one month after the surgery. The splint was removed and active ankle exercises were initiated between the first and second months. Moreover, partial weight bearing was allowed after the second month and full weight bearing was allowed after the third month.

Pain assessment was performed using Visual Analog scale (VAS 1-10) and functional outcomes were assessed using the AOFAS (American Orthopedic Foot & Ankle Society) Ankle-Hindfoot Rating System. Additionally, a questionnaire was filled out by each patient both preoperatively and at 1 year postoperatively (10) (Figure 4).

Statistical Analysis: Data were analyzed using IBM SPSS 22.0 (IBM SPSS Statistics for Windows, Armonk, NY: IBM Corp.). Both preoperative and postoperative AOFAS scores of the patients showed normal distribution on the Kolmogorov-Smirnov test; therefore, these scores were compared using a dependent t-test. However, as the pre- and postoperative VAS scores showed nonnormal distribution, they were compared using Wilcoxon signed-rank test. A p value of <0.05 was considered significant.

Results

The 23 patients comprised 15 (65.2%) men and 8 (34.8%) women with a mean age of 32.3 (range, 24-42) years. The lesion was localized in the right talus in 15 (65.2%) and in the left talus in 8 (34.8%) patients. Seventeen (73.9%) patients had a history of trauma to the ankle. Mean defect diameter was $13,8 \pm 1,43$ mm. Of the 23 patients, 9 (39,1%) patients were actively involved in sports, 12 (52,2%) patients were involved in employee 2 (8,7%) patients were housewives. The most common preoperative complaint was pain at exercise (92%), followed by recurrent swelling (75%), acute akinesia (40%), and crepitus (36%). Mean

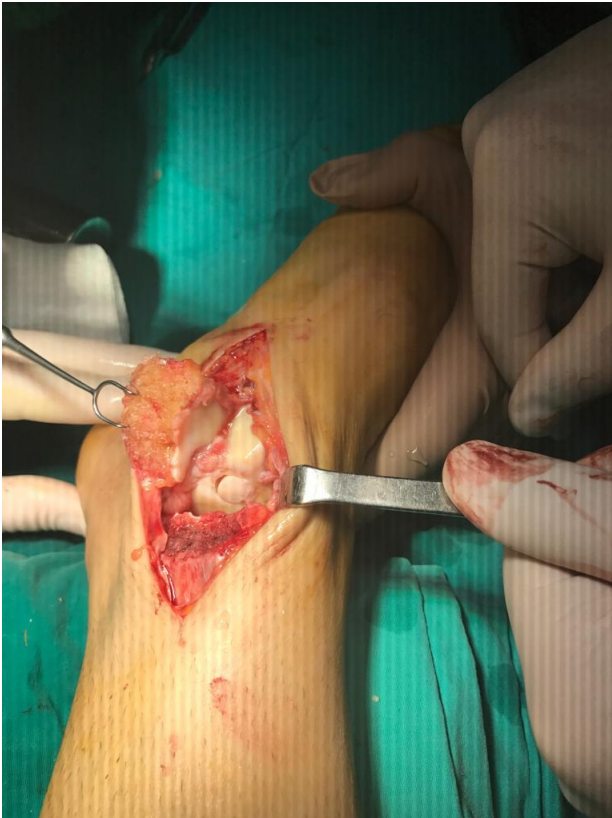

Fig. 3. Medial Malleolar Osteotomy and Mosaicplasty of the Talus

preoperative period was 13 (range, 6-30) months (Table 1).

According to the Bristol classification, 12 (52.2%) patients had a Grade III, 8 (34.8%) patients had a Grade IV, and 3 (13.0) patients had a Grade V osteochondral lesion. (Table 2)

Mean AOFAS score was 55.652 preoperatively and was 88.913 postoperatively and a significant difference was found between the two scores ($p < 0.001$). Similarly, mean VAS score was 7.39 preoperatively and was 2.04 postoperatively and a significant difference was found between the two scores ($p < 0.001$). (Table 3)

Discussion

In patients with chronic osteochondral lesions of the talus, surgical treatment is indicated if the complaints cannot be treated by conservative methods (11). However, there are various contradictions regarding surgical indications and methods (12). Moreover, the choice of surgical technique depends largely on the experience of the surgeon as well as patient-related factors and the availability of surgical services (13-14). Surgical techniques such as arthroscopic debridement and microfracture lead to mechanical insufficiency of the fibrocartilaginous structure by exposing the bone

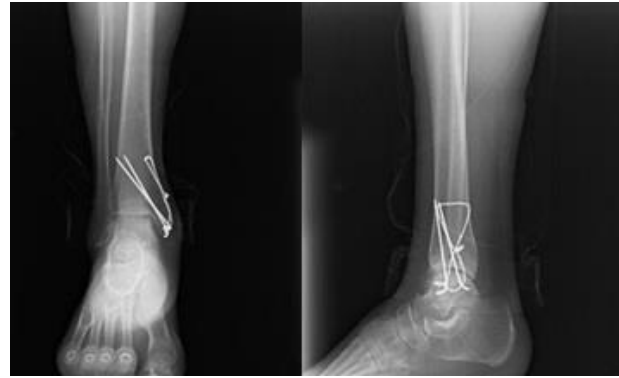

Fig. 4. Postoperative 12th month ankle anterior-posterior and lateral radiography

marrow (15). To date, various allografts have been used for hyaline cartilage regeneration and for the closure of large cartilaginous defects. However, the use of allografts has remained unpopular due to numerous unclear issues related to allografts such as disease transmission, immunological reactions, and long-term outcomes (16). On the other hand, autologous chondrocyte implantation and mosaicplasty remain the two most popular techniques for the treatment of cartilaginous defects. Of these, mosaicplasty is mostly preferred over autologous chondrocyte implantation as the latter is a two-stage procedure and is relatively more costly. Mosaicplasty is also advantageous since the spongy bone it harvests together with hyaline cartilage is highly useful for the closure of the recipient bone defect. Additionally, mosaicplasty has been shown to provide favorable long-term outcomes in osteochondral lesions measuring 10-15 mm in size. For instance, Scranton et al. reported that mosaicplasty provided an excellent outcome in 90% of the patients with a lesions measuring 8-20 mm in size (17). Similarly, Hangody et al. reported that mosaicplasty provided an excellent outcome in 88 (92%) out of 96 patients (18). Additionally, Kilic et al. revealed that open mosaicplasty is a safe, effective procedure for osteochondral lesions of the talus measuring over 10 mm in size and that it provided an excellent outcome in 89% of the patients (19). Savage-Elliott et al. compared the effectivity of mosaicplasty and microfracture and reported that mosaicplasty was superior to microfracture with regard to functional outcomes in patients with Grade V cystic lesions larger than 1.5 cm² in size (20). In the present study, mosaicplasty was concurrently performed with open surgery for osteochondral lesions of the talus. According to the objective and subjective evaluations performed at 1-year follow-up, mosaicplasty provided a favorable outcome in 89% of the patients, as consistent with the literature.

Table 1. Demographic data of patients

	Men	Women	Total
Patient	15	8	23
Right talus	8	5	13
Left talus	5	3	8
Sportmen	6	3	9
Employee	9	3	12
Housewise	-	2	2
Lateral/Plate-screw	2	1	3
Medial/Tension-band wiring	13	7	20

Table 2. Bristol classification of the patients

Bristol classification	n(count)
Grade III	12
Grade IV	8
Grade V	3
Total	23

Table 3. Functional outcomes of the patients

Functional outcomes	point	p (value)
Preoperative average VAS Score	7,39	p<0.001
Postoperative 1st year average VAS Score	2,04	
Preoperative average AOFAS score	55,652	p<0.001
Postoperative 1st average AOFS score	88,913	

In our study, open surgery was performed with mosaicplasty since the defects were difficult to access and we had no sufficient experience in arthroscopic techniques. Moreover, the administration of open surgery provided several advantages such as complete visualization of the defect site, greater press-fit impaction of the grafts, facilitation of the smoothening of the joint surface, application of the graft at different angles, lower fragility of the harvested grafts, and the facilitation of graft application. On the other hand, literature indicates that open mosaicplasty (i.e. medial and lateral malleolar osteotomy) is indicated in a significant portion of the patients with osteochondral lesions (12-21-22). Lamb et al. evaluated 62 patients who underwent medial malleolar osteotomy and reported that the median time to healing was 6 weeks and 94% of the patient were asymptomatic in terms of osteotomy after an average of follow-up period of 34 months (23). In our study, transmalleolar osteotomy was performed for osteochondral lesion of the talus by harvesting a graft from the normal knee joint. In the follow-up period, complete healing was achieved in all the patients and all the patients were asymptomatic in terms of osteotomy. In addition, it was also revealed that the administration of

concurrent mosaicplasty had no adverse effects on the outcomes and even facilitated both the procedure and graft application.

In our study, none of the complications reported in the literature occurred in any patient. To our knowledge, the largest series of patients undergoing autologous osteochondral mosaicplasty has been reported by Hangody et al., in which the authors performed mosaicplasty in 98 patients with osteochondral lesions of the talus and revealed that only 3% of the patients reported a donor-site knee pain during the long-term follow-up period (24). Similarly, Kennedy et al. performed mosaicplasty in a cohort of 72 patients and reported that 3 (4.2%) patients had a donor-site knee pain and 1 (1.4%) patient underwent the decompression of a cyst (25). Paul et al. evaluated a total of 112 patients who had transplantation of an autologous osteochondral graft obtained from a normal knee. The authors assessed functional outcome using the Lysholm score and found a mean Lysholm score of 89, which indicated an excellent outcome (26). On the other hand, Reddy et al. reported that the number of grafts taken from asymptomatic knees for the treatment of osteochondral lesions of the talus had no significant effect on the clinical outcome of the patients (27).

Our study was limited due to the small number of patients, inclusion of young-age patients, short follow-up period, and the absence of a control group.

In conclusion, open mosaicplasty appears to be a useful technique for the treatment of cystic osteochondral lesions of the talar dome larger than 10 mm in diameter. The technique is also safe and effective and allows successful closure of the cartilaginous loss with hyaline cartilage.

References

1. Berndt AL, Harty M. Transchondral fractures (osteochondritis dissecans) of the talus. *J Bone Joint Surg* 1959; 41: 988-1020.
2. Schachter AK, Chen AL, Reddy PD, Tejwani NC. Osteochondral lesions of the talus. *J Am Acad Orthop Surg* 2005; 13: 152-158.
3. Atik OS, Uslu MM, Eksioğlu F. Osteochondral multiple autograft transfer (OMAT) for the treatment of cartilage defects in the knee joint. *Bull Hosp Jt Dis* 2005; 63: 37-40.
4. Giannini S, Buda R, Faldini C, Vannini F, Bevoni R, Grandi G, et al. Surgical treatment of osteochondral lesions of the talus in young active patients. *J Bone Joint Surg [Am]* 2005; 87: 28-41.
5. Hepple S, Winson IG, Glew D. Osteochondral lesions of the talus: a revised classification. *Foot Ankle Int* 1999; 20: 789-793.
6. O'Loughlin PF, Heyworth BE, Kennedy JG. Current concepts in the diagnosis and treatment of osteochondral lesions of the ankle. *Am J Sports Med* 2010; 38: 392-404.
7. Prado MP, Kennedy JG, Raduan F, Nery C. Diagnosis and treatment of osteochondral lesions of the ankle: current concepts. *Rev Bras Ortop* 2016; 51: 489-500.
8. Murawski CD, Kennedy JG. Operative treatment of osteochondral lesions of the talus. *J Bone Joint Surg Am* 2013; 95: 1045-1054.
9. Van Dijk CN, Reilingh ML, Zengerink M, Van Bergen CJ. The natural history of osteochondral lesions in the ankle. *Instr Lect* 2010; 59: 375-386.
10. Kiota HB, Alexander IJ, Adelaar RS, Nunley JA, Myerson MS, Sanders M. Clinical rating systems for the ankle-hindfoot, midfoot, hallux, and lesser toes. *Foot Ankle Int* 1994; 15: 349-353.
11. Chodos MD, Schon LC. Osteochondral lesions of the talus: current treatment modalities and future possibilities. *Ankle and foot. Curr Opin Orthop* 2006; 17: 111-116.
12. Sexton AT, Labib SA. Osteochondral lesions of the talus: current opinions on diagnosis and management. *Sports medicine. Curr Opin Orthop* 2007; 18: 166-171.
13. Lee CH, Chao KH, Huang GS, Wu SS. Osteochondral autografts for osteochondritis dissecans of the talus. *Foot Ankle Int* 2003; 24: 815-822.
14. Al-Shaikh RA, Chou LB, Mann JA, Dreeben SM, Prieskorn D. Autologous osteochondral grafting for talar cartilage defects. *Foot Ankle Int* 2002; 23: 381-389.
15. Messner K, Gillquist J. Cartilage repair. A critical review. *Acta Orthop Scand* 1996; 67: 523-529.
16. Friedlaender GE, Horowitz MC. Immune responses to osteochondral allografts: nature and significance. *Orthopedics* 1992; 15: 1171-1175.
17. Scranton PE Jr, McDermott JE. Treatment of type V osteochondral lesions of the talus with ipsilateral knee osteochondral autografts. *Foot Ankle Int* 2001; 22: 380-384.
18. Hangody L, Dobos J, Baló E, et al. Clinical experiences with autologous osteochondral mosaicplasty in an athletic population: a 17-year prospective multicenter study. *Am J Sports Med* 2010; 38: 1125-1133.
19. Kiliç A, Kabukçuoğlu Y, Gül M, Ozkaya U, Sökücü S. [Early results of open mosaicplasty in osteochondral lesions of the talus]. *Acta Orthop Traumatol Turc* 2009; 43: 235-242.
20. Savage-Elliot I, Ross KA, Smyth NA, Murawski CD, Kennedy JG. Osteochondral lesions of the talus: current concepts review and evidence-based treatment paradigm. *Foot Ankle Specialist* 2014; 7: 5414-5422
21. Scranton PE Jr. Osteochondral lesions of the talus: autograft and allograft replacement. *Tech Foot Ankle Surg* 2004; 3: 25-39.
22. Sasaki K, Ishibashi Y, Sato H, Toh S. Arthroscopically assisted osteochondral autogenous transplantation for osteochondral lesion of the talus using a transmalleolar approach. *Arthroscopy* 2003; 19: 922-927.
23. Lamb J, Murawski CD, Deyer TW, Kennedy JG. Chevron-type medial malleolar osteotomy: a functional, radiographic and quantitative T2-mapping MRI analysis. *Knee Surg Sports Traumatol Arthrosc* 2013; 21: 1283-1288.
24. Hangody L, Vásárhelyi G, Hangody LR, Sükösd Z, Tibay G, Bartha L. Autologous osteochondral grafting--technique and long-term results. *Injury* 2008; 32-39.
25. Kennedy JG, Murawski CD. The treatment of osteochondral lesions of the talus with autologous osteochondral transplantation and bone marrow aspirate concentrate: surgical technique. *Cartilage* 2011; 2: 327-336.

26. Paul J, Sagstetter A, Kriner M, Imhoff AB, Spang J, Hinterwimmer S. Donor-site morbidity after osteochondral autologous transplantation for lesions of the talus. *J Bone Joint Surg Am* 2009; 91: 1683-1688.
27. Reddy S, Pedowitz DI, Parekh SG, Sennett BJ, Okereke E. The morbidity associated with osteochondral harvest from asymptomatic knees for the treatment of osteochondral lesions of the talus. *Am J Sports Med* 2007; 35: 80-85.