

Agreement Between Endocervical Brush and Endocervical Curettage in the Diagnosis of Cervical Cancer

Melih Bestel^{1*}, Baki Erdem², Aysegul Bestel¹, Onur Karaaslan³

¹Obstetric and Gynecology Clinic, Tekirdag State Hospital, Tekirdag, Turkey

²Obstetric and Gynecology Clinic, University of Health Sciences Kanuni Sultan Süleyman Research and Training Hospital, İstanbul, Turkey

³Obstetric and Gynecology Clinic, Hakkari State Hospital, Hakkari, Turkey

ABSTRACT

Cervical cancer is one of the most common gynecologic cancer, and endocervical curettage (ECC) and endocervical brush (ECB) can be used in the diagnosis of cervical cancer. In this study, it was aimed to investigate the agreement between two methods and evaluate whether more invasive ECC may be replaced with ECB.

The data of obstetric patients who were admitted to the Gynecology and Obstetrics Clinic of a tertiary health care center in 2016 were retrospectively reviewed. A total of 170 patients were referred for colposcopy due to abnormal Papanicolaou test (Pap smear) results and / or high-risk human papilloma virus (HPV) positivity. All patients were examined without anesthesia through colposcopically directed biopsies and underwent cervical sampling with ECC and ECB. The ECB and ECC samples were grouped as negative, low-grade, and high-grade.

ECB was negative in 132 (83.5%) of 158 patients with negative ECC results. Four patients with low-grade ECC results also had low-grade ECB results (100%). Of 8 patients with high-grade ECC results, only 4 patients (50%) had high-grade ECB results. Regarding all the data, a moderate degree of agreement was found between the two methods with an intraclass correlation coefficient of 0.503 (95% CI: [0.327-0.633], $p < 0.001$).

Considering the moderate agreement between the two methods and the fact that ECB is less invasive, it can be concluded that ECC may be replaced with ECB at the patient level.

Key Words: Cervical cancer, endocervical brush, endocervical curettage

Introduction

Cervical cancer is the third most commonly diagnosed gynecologic cancer (1). It originates from pre-invasive lesions or cervical dysplasias arising from squamous and glandular cells in the cervical region (2). About 79.6% of these cancers are squamous and 19.2% are adenocarcinoma (3). Most cervical cancers begin in the cells in the transformation zone, which may vary depending on the age and hormonal status of the patient (2). The Papanicolaou test (Pap smear) is a non-invasive procedure used in the screening of pre-invasive lesions and cervical dysplasia (4). Human papilloma virus (HPV) infection is causative for cervical cancer, thus HPV screening can also be performed to screen for cervical cancer. In the presence of abnormal Pap smear results and/or high-risk HPV positivity, endocervical canal

sampling is performed with colposcopy for the diagnosis of cervical cancer (5,6).

Endocervical canal sampling can be performed either with a curette or with a less-invasive endocervical brush (ECB) (7). Although ECBs cause less patient discomfort than endocervical curettage (ECC), it has been shown in various publications that ECBs are associated with high false positivity (8,9). However, there are also publications showing that there are no differences between the two methods in terms of diagnostic validity (10). The use of ECBs in postmenopausal women with cervical stenosis and in pregnant women has been shown to be easier and more comfortable for the patients (11,12).

In this study, the clinical and demographic characteristics of patients with abnormal Pap smear result and/or high-risk HPV positivity were reviewed, and the agreement between ECC and ECB methods was examined.

*Corresponding Author: Melih Bestel, Obstetric and Gynecology Clinic, Tekirdag State Hospital, Tekirdag, Turkey
E-mail: melihbestel@gmail.com, Phone:+90 (535) 920 5723

Received: 01.04.2018, Accepted: 29.12.2018

Table 1. Demographic and clinical characteristics of patients

Mean age, mean±SD	40.2 ± 9.86
Gravida, mean±SD	3 ± 2.3
Parity, mean±SD	2.3 ± 1.79
Abortus, mean±SD	0.2 ± 0.57
Curettage, mean±SD	0.5 ± 0.95
High-risk HPV positivity, n (%)	40 (23.6%)
Only high-risk HPV positivity	20 (11.8%)
Abnormal pap smear and high-risk HPV positivity	20 (11.8%)
Postmenopausal, n (%)	
Yes	24 (14.1%)
No	146 (85.9%)
Smoking, n (%)	
Yes	53 (31.2%)
No	117 (68.8%)
Oral contraceptive use, n (%)	
Yes	34 (20%)
No	136 (80%)
Endocervical curettage result, n (%)	
Negative	158 (92.9%)
CIN 1	4 (2.4%)
CIN 2	4 (2.4%)
CIN 3	4 (2.4%)
Endocervical brush result, n (%)	
Negative	136 (80%)
ASC-US	13 (7.6%)
LSIL	10 (5.9%)
HSIL	10 (5.9%)
ASC-H	1 (0.6%)

HPV: Human papilloma virus, CIN: Cervical intraepithelial neoplasia, ASC-US: Atypical squamous cells of undetermined significance, LSIL: Low-grade squamous intraepithelial lesions, HSIL: High-grade squamous intraepithelial lesions, ASC-H: Atypical squamous cells-cannot rule out high-grade squamous intraepithelial lesion, SD: Standard deviation

Materials and Methods

Patient Selection and Sample Collection: In the present study, the data of obstetric patients

who were admitted to the Gynecology and Obstetrics Clinic of a tertiary health care center in 2016 were retrospectively reviewed. A total of 170 patients were referred for colposcopy due to

Table 2. Comparing clinical and demographic features between HPV positive and negative groups

	HPV negative (n=130)	HPV positive (n=40)	p value
Age (year), mean \pm SD	39.7 \pm 9.46	42.4 \pm 10.24	0.226
Gravida, mean \pm SD	3.2 \pm 2.44	2.6 \pm 1.95	0.255
Parity, mean \pm SD	2.4 \pm 1.86	2.1 \pm 1.52	0.576
Abortus, mean \pm SD	0.3 \pm 0.61	0.2 \pm 0.43	0.273
Curettage, mean \pm SD	0.6 \pm 1.04	0.3 \pm 0.62	0.337
Smoking, n	39	14	0.563
OCS use, n	27	7	0.822
Menopause status, n	15	9	0.116

HPV: Human papilloma virus, SD: Standard deviation, OCS: Oral contraceptive

Table 3. Correlation between ECC and ECB results, and age, gravida, parity, abortus, curettage

	ECC	ECB
Age	r = 0.149, p = 0.053	r = 0.037, p = 0.629
Gravida	r = 0.053, p = 0.493	r = 0.043, p = 0.579
Parity	r = 0.086, p = 0.267	r = 0.057, p = 0.457
Abortus	r = -0.014, p = 0.856	r = 0.104, p = 0.177
Curettage	r = 0.023, p = 0.771	r = -0.087, p = 0.258

ECC: Endocervical curettage, ECB: Endocervical brush

abnormal Pap smear results and/or high-risk HPV positivity. All patients were examined without anesthesia through colposcopically directed biopsies and underwent cervical sampling with ECC and ECB. Patients who did not have detailed medical records and those who were pregnant were excluded from the study.

Patients were evaluated for age, gravida, parity, abortion, curettage, menopause, oral contraceptive (OCS) use, and smoking. Pap smears were made using the conventional technique and reported in accordance with the Bethesda classification (13). Abnormalities of epithelial cells were accepted as abnormal Pap smears. High-risk HPV types were identified as types 16, 18, 31, 33, 35, 39, 45, and 58 (14).

ECB sampling was performed using a standard endocervical brush, which was placed in the cervical canal and rubbed firmly during the rotation process to ensure that the entire canal was sampled. The sample on the brush was then dipped in 10% formalin. ECC sampling was performed using a 3-mm Kevorkian curette with basket making a 4-quadrant sweep of the endocervix. The curette was swished in formalin to remove cells. All procedures were performed by two experienced gynecologists and obstetricians.

The ECB results were grouped as negative, low-grade, and high-grade. The low-grade group included low-grade squamous intraepithelial lesions (LSIL) and atypical squamous cells of undetermined significance (ASC-US). The high-grade group included high-grade

squamous intraepithelial lesions (HSIL) and atypical squamous cells/cannot rule out high-grade squamous intraepithelial lesion (ASC-H). The ECC results were then similarly grouped as negative, low-grade, and high-grade. The low-grade group included cervical intraepithelial neoplasia (CIN) 1, and the high-grade group included CIN 2 and CIN 3. All samples were studied at the same laboratory.

Statistical Analysis: Statistical analysis was performed using the SPSS 21.0 (IBM SPSS Statistics, IL, USA) software package. Intra-class correlation coefficient was calculated for agreement between ECB and ECC based on negative, low- and high-grade groups. The Chi-square, t-test or Mann-Whitney U test were used for intergroup comparisons of clinical features, where appropriate. Correlation analysis was performed using Spearman's correlation test. $p < 0.05$ was used as the cutoff for significance.

Results

Clinical and Demographic Features: The mean age of the patients was 40.2 ± 9.86 years. The mean gravida was 3 ± 2.3 , the mean parity was 2.3 ± 1.79 , the mean number of abortions was 0.2 ± 0.57 , and mean number of curettages was 0.5 ± 0.95 . Twenty-four (14.1%) patients were postmenopausal. Fifty-three (31.2%) patients were smokers and 34 (20%) were using OCS (Table 1).

Evaluation and Comparison of Sampling Results: Forty (23.6%) patients had high-risk HPV positivity.

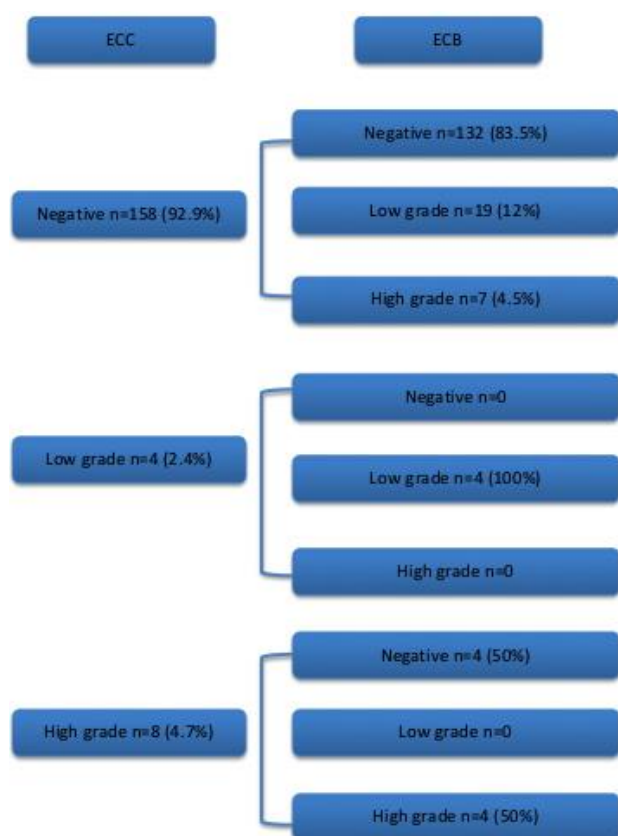


Fig.1. Endocervical brush (ECB) was negative in 83.5% of 158 patients who had negative endocervical curettage (ECC) results. Four patients with low-grade ECC results also had low-grade ECB results. Only 50% of 8 high-grade ECC patients had high-grade ECB results

Twenty (11.8%) patients had abnormal Pap smears and high-risk HPV positivity. Regarding age, gravida, parity, abortion, and curettage, HPV-positive and negative groups did not differ significantly (Table 2). It was observed that HPV positivity was not related to menopause status, smoking, and OCS use (Table 2). There was no correlation between ECC and ECB results, and age, gravida, parity, abortus, curettage (Table 3).

When ECC results were evaluated, it was observed that 158 (92.9%) patients had negative results, and 4 (2.4%) patients had low-grade and 8 (4.7%) patients had high-grade results. ECB results were negative in 136 (80%) patients, low-grade in 23 (13.5%) patients, and high-grade in 11 (6.5%) patients. The detailed distribution of subtypes is given in Table 1. ECB was negative in 132 (83.5%) of 158 patients with negative ECC results. Four patients with low-grade ECC results also had low-grade ECB results (100%). Of 8 patients with high-grade ECC results, only 4 patients (50%) had high-grade ECB results (Figure 1). Regarding all the data, a moderate degree of agreement was found between the two methods with an intraclass correlation coefficient (ICC) of 0.503 (95% CI: [0.327-0.633], $p < 0.001$).

Discussion

In this study, moderate agreement was found between ECB and ECC. When an intergroup comparison was performed for the subgroups, we observed an increase in agreement in the negative and low-grade groups. However, the agreement level decreased by half in the high-grade group. Demographic and clinical variables were not associated in terms of agreement between ECB and ECC. As these factors could be altered due to biologic potentiality, further research is essential for the assessment of possible associations.

Although the American Society for Colposcopy and Cervical Pathology (ASCCP) stated that both methods could be used in the evaluation of patients for endocervical pathologies, there are several conflicting studies in the literature about the sensitivity and specificity of these methods and their agreement. In a study comparing the two methods, the sensitivity and specificity of ECB were found to be higher than that of ECC, but the results did not reach statistical significance. When the researchers evaluated their agreement, they found high agreement between the two methods and suggested that ECB could be preferred (15). Most of the patients evaluated in that study had low-grade results. Similarly, patients in the negative and low-grade groups showed higher agreement in our study group. In this respect, it can be postulated that these two tests show higher agreement in low-grade results. However, the number of high-grade results is quite low in both studies, and this can be considered to cause statistical errors in the calculation of agreement. In a study conducted by Doo et al. in 79 patients, there was poor agreement between the two methods and this was attributed to the small number of patients or changes in the lesions due to different sampling times (16). The higher agreement in our study could be influenced by the fact that our sampling times were the same.

In practical use, the samples taken using ECB can be screened for HPV and no further procedures are required in this scenario. Although not included in this study, sampling with ECBs in pregnant women also reduces the risks to the pregnancy (8). Considering the fact that 14.1% of the patients in this study were in the postmenopausal period, it was difficult to perform ECC due to cervical canal stenosis in these patients; ECB facilitates the cervical canal sampling process in this group. In this respect, it is promising that we found moderate agreement.

The strengths of this study are that it was performed with a very large group of patients and both procedures were performed simultaneously in the

same patient group. However, the small number of patients with low-grade and high-grade results is a limitation. Further studies with more patients with low-grade and high-grade results would be helpful in this regard. In addition, it is difficult to say which method gave the results closer to the actual results because there was no pathologic diagnosis that we could compare in both methods.

Considering the moderate agreement between the two methods and the fact that ECB is less invasive, it can be concluded that ECC may be replaced with ECB at the patient level. However, more extensive studies are needed to provide precise results.

Acknowledgement: Special thanks to David Chapman for language editing.

Conflict of interests: None declared.

Funding: None.

References

1. Richardson DL. Cervical cancer. In: Hoffman BL et al. Williams Gynecology (3rd ed) 2016; 657-679.
2. Undurraga M, Catarino R, Navarria I, et al. User perception of endocervical sampling: A randomized comparison of endocervical evaluation with the curette vs. cytobrush. PLoS One 2017; 12: e0186812.
3. Gultekin M, Kucukyildiz I, Karaca MZ, et al. Trends of Gynecological Cancers in Turkey: Toward Europe or Asia? Int J Gynecol Cancer 2017; 27: 1525-1533.
4. Kim HS, Park JS, Park JY, et al. Comparison of two preparation methods for endocervical evaluation. Acta Cytol 2007; 51: 742-748.
5. Saslow D, Solomon D, Lawson HW, et al. American Cancer Society, American Society for Colposcopy and Cervical Pathology, and American Society for Clinical Pathology screening guidelines for the prevention and early detection of cervical cancer. Am J Clin Pathol 2012; 137: 516-542.
6. IARC Working Group on the Evaluation of Carcinogenic Risks to Humans. Human papillomaviruses. IARC Monogr Eval Carcinog Risks Hum 2007; 90: 1-636.
7. Hoffman MS, Sterghos S Jr, Gordy LW, Gunasekaran S, Cavanagh D. Evaluation of the cervical canal with the endocervical brush. Obstet Gynecol 1993; 82: 573-577.
8. Weitzman GA, Korhonen MO, Reeves KO, Irwin JF, Carter TS, Kaufman RH. Endocervical brush cytology. An alternative to endocervical curettage? J Reprod Med 1988; 33: 677-683.
9. Andersen W, Frierson H, Barber S, Tabbarah S, Taylor P, Underwood P. Sensitivity and specificity of endocervical curettage and the endocervical brush for the evaluation of the endocervical canal. Am J Obstet Gynecol 1988; 159: 702-707.
10. Dunn TS, Stevens-Simon C, Moeller LD, Mickle S. Comparing endocervical curettage and endocervical brush at colposcopy. J Low Genit Tract Dis 2000; 4: 76-78.
11. Martin D, Umpierre SA, Villamarzo G, et al. Comparison of the endocervical brush and the endocervical curettage for the evaluation of the endocervical canal. P R Health Sci J 1995; 14: 195-197.
12. Paraiso MF, Brady K, Helmchen R, Roat TW. Evaluation of the endocervical Cytobrush and Cervex-Brush in pregnant women. Obstet Gynecol 1994; 84: 539-543.
13. Nayar R, Wilbur DC. The Pap test and Bethesda 2014. Cancer Cytopathol 2015; 123: 271-281.
14. Werner CL. Preinvasive Lesions of the Lower Genital Tract. In: Hoffman BL et al. Williams Gynecology (3rd ed) 2016; 624-657.
15. Mogensen ST, Bak M, Dueholm M, et al. Cytobrush and endocervical curettage in the diagnosis of dysplasia and malignancy of the uterine cervix. Acta Obstet Gynecol Scand 1997; 76: 69-73.
16. Doo DW, Stickrath EH, Mazzoni SE, Alston MJ. Lack of Agreement Between Endocervical Brush and Endocervical Curettage in Women Undergoing Repeat Endocervical Sampling. J Low Genit Tract Dis 2016; 20: 296-299.