

Comparison of Cleft Lift and Limberg Flap Techniques For Pilonidal Sinus Surgery

Orhan Agcaoglu^{1*}, Ahmet Cem Dural², Candas Ercetin³, Tugan Tezcaner⁴, Mahir Kirnap⁴, Turgut Anuk⁵

¹Department of General Surgery, Koç University, Istanbul, Turkey

²Department of General Surgery, Bakırköy Dr. Sadi Konuk Training and Research Hospital, Istanbul, Turkey

³Department of General Surgery, Bağcılar Training and Research Hospital, Istanbul, Turkey

⁴Department of General Surgery, Başkent University, Ankara, Turkey

⁵Department of General Surgery, Kafkas University, Kars, Turkey

ABSTRACT

Sacrococcygeal pilonidal disease is an infection and also chronic inflammation of the sacral region which has been generally seen in young patient population. Though, numerous surgical techniques have been described in the medical literature, a recent Cochrane review shows that the resection with an off-midline close technique should be chosen to conventional primary midline closure due to its advantages including lower recurrence rates and faster wound healing. The aim of this study was to compare the outcomes of the Cleft-lift (CL) versus Limberg-flap (LF) techniques.

Between 2007 and 2009, a total of 131 patients with sacrococcygeal pilonidal disease were randomized into two study groups regarding the operative technique of CL [Group-1 (G1)] and LF [Group-2 (G2)]. Patients with prior abscess drainage were excluded from the study. Groups were compared regarding the recurrence, operation time, duration of hospital stay and other morbidities. Data were collected retrospectively from patients charts and department database.

There were 60 patients in group 1 and 71 patients in group 2. The mean age of the patients was 20.2 years (16-33). The mean operative time of group 1 (43.2 ± 7.9 minutes) was significantly shorter than group 2 (52.6±8.6 minutes) (p<0.01).

There were no significant differences between study groups regarding hospital stay, wound infection and recurrences.

In conclusion, CL procedure was found to be as effective as the LF technique due to advantage of shorter operative time and similar safety outcomes.

Key Words: Pilonidal sinus; Cleft lift; Limberg flap

Introduction

Sacrococcygeal pilonidal sinus (SPS) disease is a common health problem affecting mostly young male population that mainly develops within lower midline sinuses in the natal cleft (1). SPS ordinarily exist as an abscess or a sinus tract on the natal cleft with seropurulent discharge (2). Although numerous surgical techniques have been reported in the literature, there is still no consensus for the ideal method for treatment of SPS from abscess drainage to complex advanced off-midline flap mobilizations (3,4). Similar to other surgical techniques, the success of pilonidal sinus surgery can be measured by the rates of complications, recurrence and healing time of the disease. Modification of the midline and positioning of the incision scar to the cleft are the most important factors in wound healing, in addition, a recent Cochrane study reported that

off-midline closure techniques should be the standard treatment method in SPS disease (5).

Among these off-midline closure flap techniques, the most common one is LF. This technique consisted of a rhomboid shaped excision of the diseased region that repaired by medial mobilization of a tension free fasciocutaneous flap on the gluteal region. The other off-midline method is the CL technique which was first reported by Bascom in 2002 (6). Although there is scant data about this technique in the literature, few studies noted such advantages as faster healing time and better recurrence rates (7-9).

The aim of this study was to compare the results of CL versus LF techniques for the management of SPS disease.

Materials and Methods

One hundred and thirty-one consecutive patients who underwent pilonidal sinus surgery between

*Corresponding Author: Orhan Agcaoglu, Davutpasa Cad. No:4 Topkapi / Istanbul post code:34337

E-mail: oagcaoglu@gmail.com, Phone: +90 (532) 515 71 65

Received: 06.03.2019, Accepted: 08.05.2019

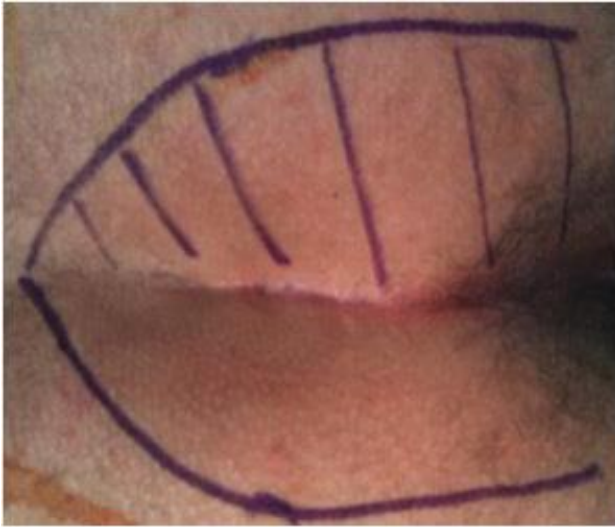

Fig. 1. The mapping of the buttock outer line of contact

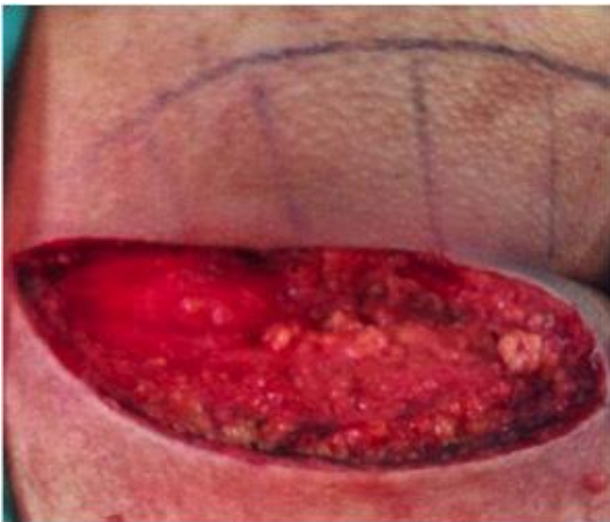


Fig. 2. Intra operative photo of the excised diseased area

September 2007 to December 2009 were included to the study. Patients with prior abscess drainage were excluded from the study. All patients were healthy adults without any other co-morbidities. Data of the patients were obtained retrospectively from patient charts and department database. All patients were treated either by CL procedure (G1) or LF technique (G2). Study groups were compared in terms of recurrence rate, operation time, length of hospital stay and complications.

Operative Techniques: In each study groups, a single dose of prophylactic intravenous antibiotics (a third generation cephalosporin) was intravenously administered 30 minutes prior to surgery. The CL process was done as defined in literature as follows (6). After the mapping of the buttock outer line of contact (figure-1), and the

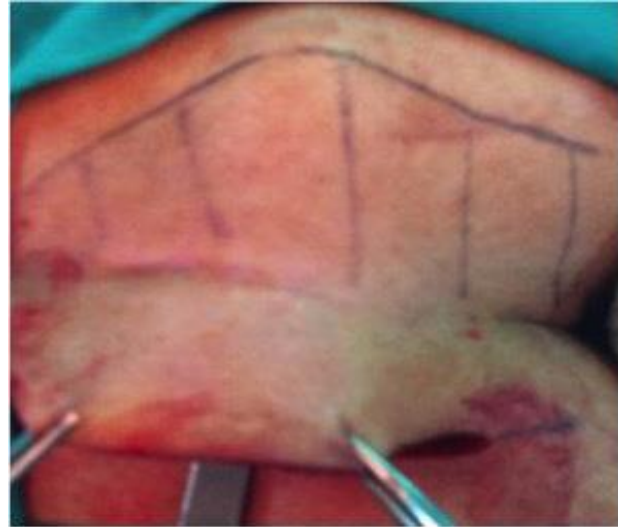


Fig. 3. The skin on the opposite side of the cleft was mobilized by freeing from the underlying tissue out past the edge of the natal cleft on the other side

diseased area was excised (figure-2). Then skin on the contrary side of the cleft was mobilized by freeing from the underlying tissue out past the edge of the natal cleft on the other side (figure-3). The medially transposed fasciocutaneous flap was sutured in two layers including the subcutaneous tissue with absorbable (3/0 polyglactin) sutures and skin with non-absorbable (3/0 polypropylene) interrupted mattress sutures. LF technique was done according to the technique which was noted by Mentis et al. (10). After the skin marking of the diseased area which was planning to be excised, we administered a blue dye to the sinus pores for guidance. Then, a rhomboid excision was done to the pre-sacral fascia. A right or left sided fasciocutaneous flap including gluteal fascia was totally mobilized medially to fill the defect.

In both techniques the patients were placed in the prone jack-knife position, the buttocks were drawn to the sides by tapes, and an aspirative drain was placed beneath the flap and brought out laterally through a 5mm stab incision.

Statistical Analyses: The statistical analyses were performed by using SPSS 16 (SPSS Inc., Chicago, IL, USA). Chi-square test was used for nominal data, Mann-Whitney U statistical analyses was used for ordinal data. P value of <0.05 was considered statistically significant.

Results

A total of 131 patients were included to the study. There were 60 patients in G1 and 71 patients in G2. The mean age of the patients was 20 years

Table 1. Comparison between study groups

	Cleft Lift (Group-1)	Limberg Flap (Group-2)	P
Number of patients	60	71	
Gender (Male/Female)	46/14	56/15	0.761
Hospital Stay (Day)	1.3	1.2	0.892
Duration of drain (Day)	1	1	0.904
Wound infection	6 (10%)	7 (10%)	0.978
Recurrence	2 (3.3%)	4 (5.6%)	0.530

(range 16-33) and male/female ratio was 102/29. The mean operative time of G1 (43.2 ± 7.9 minutes) was significantly shorter than G2 (52.6 ± 8.6 minutes) ($p < 0.01$). There were no significant differences between study groups regarding hospital stay, wound infection and recurrences (Table 1). Suction drains were taken out on postoperative day 1 in all cases. The patients mean follow up period was 86.4 versus 98.8 months, respectively. The recurrence ratio of the study groups was 3.3% in G1 and 5.6% in G2.

Discussion

According to the current literature, the main etiology of the SPS disease is the anaerobic environment and moisture of the deep natal cleft (11,12), however, this etiopathogenesis of the disease is still controversial. Regarding to eliminate the pathogenesis of the disease, many surgical techniques have been noted in literature for an optimal management algorithm with low recurrence and complication rates, but it has still not been accomplished (13).

During the last decades, flap techniques became more popular for the treatment of the SPS disease, and numerous authors demanded that flap techniques are superior to conventional open techniques or primary closure procedures (14,15). Among these flap techniques, LF technique have gained the favor of many surgeons with low recurrence and complication rates compared to other flap procedures (13,16-18) since Azab et al. (19) reported their results. The main purpose of off-midline procedures is to use oblique or asymmetrical flaps to retain incision scars out of the midline in order to overcome tension associated problems. Moreover, recent studies regarding flap techniques reported that, off-midline techniques look like to be related to reduced pain compared to conventional midline closure techniques (20,21).

Another off-midline flap technique is the CR procedure which was first described by Bascom in

2002 (6). The author mentioned that, this technique reduces the recurrence rate by flattening the natal cleft by medial mobilization of a tension free fasciocutaneous flap on the gluteal region which removes a key factor of the pathogenesis for the disease, thus, many authors noted that the CL technique is safe and feasible with low recurrence rates and cosmetic results (8,22,23).

Although there is still insufficient data in the literature regarding the compare of CL procedure with LF technique, there are studies reporting the comparison of LF with primary closure techniques in which LF causes less post-operative pain and recurrence rates (15,24).

In our study, the compare of two techniques showed that both techniques were similar in terms of complications, rate of recurrence, length of hospital stay, and duration of suction drains, however, there was a statistically significant difference between two groups related to operative time which was longer in G2. According to the literature, the surgical site infection rate is 8% to 26% after SPS surgery (25,26). Our wound infection rate was similar to the literature with a rate of 10% in both of the groups.

A recent Cochrane review has demonstrated benefits of off-midline primary closure techniques compared to midline closure techniques or lay-open techniques (20). Moreover, Horwood et al. reported considerable benefits of the use of LF procedure for the management of chronic SPS disease over the other treatment modalities (27). However, in another prospective randomized study, Guner et al. reported that the CL procedure presents a better early quality of life and a shorter operation time than LF technique (7). When we compare our results with the literature, we noted that, the results of our study were similar to Guner et al. (7) in which we demonstrate that Cleft lift procedure is a reliable technique similar to LF technique with the advantage of shorter operative time and better cosmetic results. The main limitations of our study included being a retrospective design, lack of cosmetic results,

post-operative pain scores, and time needed to return to daily life.

In conclusion, cleft lift procedure was found to be as effective as the LF reconstruction with the advantages of shorter operative time, being less invasive and better cosmetic results. We believe that our study provides benefits of Cleft lift technique, but further prospective randomized studies needed for more accurate compare for these two techniques.

References

1. Humphries AE, Duncan JE. Evaluation and management of pilonidal disease. *Surg Clin North Am* 2010; 90: 113-124.
2. Schoeller T, Wechselberger G, Otto A. et al. Definite surgical treatment of complicated recurrent pilonidal disease with a modified fasciocutaneous V-Y advancement flap. *Surgery*. 1997; 121: 258-263.
3. Bascom J. Skin flaps for pilonidal disease. *Ann Plast Surg* 1998; 41: 338.
4. Nursal TZ, Ezer A, Caliskan K. et al. Prospective randomized controlled trial comparing V-Y advancement flap with primary suture methods in pilonidal disease. *Am J Surg* 2010; 199: 170-177.
5. McCallum IJ, King PM, Bruce J. Healing by primary closure versus open healing after surgery for pilonidal sinus: systematic review and meta-analysis. *BMJ* 2008; 336: 868-871.
6. Bascom J, Bascom T. Failed pilonidal surgery: new paradigm and new operation leading to cures. *Arch Surg* 2002; 137: 1146-1150.
7. Guner A, Boz A, Ozkan OF. et al. Limberg flap versus Bascom cleft lift techniques for sacrococcygeal pilonidal sinus: prospective, randomized trial. *World J Surg* 2013; 37: 2074-2080.
8. Bascom J, Bascom T. Utility of the cleft lift procedure in refractory pilonidal disease. *Am J Surg* 2007; 193: 606-609.
9. Abdelrazeq AS, Rahman M, Botterill ID. et al. Short-term and long-term outcomes of the cleft lift procedure in the management of nonacute pilonidal disorders. *Dis Colon Rectum* 2008; 51: 1100-1106.
10. Menten O, Bagci M, Bilgin T. et al. Limberg flap procedure for pilonidal sinus disease: results of 353 patients. *Langenbecks Arch Surg* 2008; 393: 185-189.
11. Kitchen PR. Pilonidal sinus: experience with the Karydakias flap. *Br J Surg* 1996; 83: 1452-1455.
12. Bascom J. Pilonidal disease: origin from follicles of hairs and results of follicle removal as treatment. *Surgery* 1980; 87: 567-572.
13. Petersen S, Koch R, Stelzner S. et al. Primary closure techniques in chronic pilonidal sinus: a survey of the results of different surgical approaches. *Dis Colon Rectum* 2002; 45: 1458-1467.
14. Mahdy T. Surgical treatment of the pilonidal disease: primary closure or flap reconstruction after excision. *Dis Colon Rectum* 2008; 51: 1816-1822.
15. Jamal A, Shamim M, Hashmi F. et al. Open excision with secondary healing versus rhomboid excision with Limberg transposition flap in the management of sacrococcygeal pilonidal disease. *J Pak Med Assoc* 2009; 59: 157-160.
16. Urhan MK, Küçükkel F, Topgul K. et al. Rhomboid excision and Limberg flap for managing pilonidal sinus: results of 102 cases. *Dis Colon Rectum* 2002; 45: 656-659.
17. Kapan M, Kapan S, Pekmezci S. et al. Sacrococcygeal pilonidal sinus disease with Limberg flap repair. *Tech Coloproctol* 2002; 6: 27-32.
18. Tekin A. A simple modification with the Limberg flap for chronic pilonidal disease. *Surgery* 2005; 138: 951-953.
19. Azab AS, Kamal MS, Saad RA. et al. Radical cure of pilonidal sinus by a transposition rhomboid flap. *Br J Surg* 1984; 71: 154-155.
20. Al-Khamis A, McCallum I, King PM. et al. Healing by primary versus secondary intention after surgical treatment for pilonidal sinus. *Cochrane Database Syst Rev* 2010; CD006213.
21. Akca T, Colak T, Ustunsoy B. et al. Randomized clinical trial comparing primary closure with the Limberg flap in the treatment of primary sacrococcygeal pilonidal disease. *Br J Surg* 2005; 92: 1081-1084.
22. Theodoropoulos GE, Vlahos K, Lazaris AC. et al. Modified Bascom's asymmetric midgluteal cleft closure technique for recurrent pilonidal disease: early experience in a military hospital. *Dis Colon Rectum* 2003; 46: 1286-1291.
23. Tezel E, Bostanci H, Anadol AZ. et al. Cleft lift procedure for sacrococcygeal pilonidal disease. *Dis Colon Rectum* 2009; 52: 135-139.
24. Nordon IM, Senapati A, Cripps NP. A prospective randomized controlled trial of simple Bascom's technique versus Bascom's cleft closure for the treatment of chronic pilonidal disease. *Am J Surg* 2009; 197: 189-192.
25. Ersoy E, Devay AO, Aktimur R. et al. Comparison of the short-term results after Limberg and Karydakias procedures for pilonidal disease: randomized prospective analysis of 100 patients. *Colorectal Dis* 2009; 11: 705-710.

26. Al-Khayat H, Al-Khayat H, Sadeq A. et al. Risk factors for wound complication in pilonidal sinus procedures. *J Am Coll Surg* 2007; 205: 439-444.
27. Horwood J, Hanratty D, Chandran P. et al. Primary closure or rhomboid excision and Limberg flap for the management of primary sacrococcygeal pilonidal disease? A meta-analysis of randomized controlled trials. *Colorectal Dis* 2012; 14: 143-151.