

Perioperative Results of Patients Undergoing Laparoscopic Cornual Resection and Cornuotomy in Cornual Pregnancy; Three Years Experiences of a Tertiary Referral Center

Pınar Kadiroğulları*, Hüseyin Kıyak, Kerem Doğa Seçkin

Istanbul Health Sciences University, Kanuni Sultan Suleyman Research and Training Hospital, Department of Obstetrics and Gynecology

ABSTRACT

Cornual pregnancy is a rare form of ectopic pregnancy that accounts for 2 to 4% of ectopic pregnancies, with a mortality rate of 2.0 to 2.5%. Traditionally, interstitial pregnancies were treated by medical treatment (methotrexate) or by laparotomy, cornual resection or hysterectomy. We aimed to report perioperative outcomes in these series of patients treated with laparoscopic surgery for cornual ectopic pregnancy.

The data of the patients who underwent laparoscopic surgery for interstitial pregnancy (n=10) were retrospectively reviewed. Demographic characteristics of the patients such as age, gravida, parity, predisposing factors were examined. Complaints of admission, operation and duration, preoperative and postoperative hemoglobin levels, size of pregnancy materials, length of hospital stay and complications were evaluated.

Eight patients underwent laparoscopic cornual resection and two patients underwent laparoscopic cornuotomy. The mean age of the patients included in the study was 29.5 ± 4.0 years, gravida 2.2 ± 1.1 , parity 0.7 ± 0.82 , delta hemoglobin 1.19 ± 0.57 g/dl. Abnormal bleeding and inguinal pain were the most common symptoms in symptomatic patients. The mean operation time was 64.5 ± 22.6 (40-120) minutes. The mean hospital stay of the operated patients was 2.7 ± 0.67 days.

Laparoscopic treatment of cornual ectopic pregnancies is an appropriate and safe treatment option. In our experience, the laparoscopic approach minimizes overall blood loss without causing trauma and allows a bloodless area for anatomic restoration. We believe that laparoscopic cornual resection and cornuotomy can be performed successfully in the hands of experienced surgeons and the future fertility chances of the patients can be preserved.

Key Words: Cornual ectopic pregnancy, Laparoscopy, cornual wedge resection, cornuotomy

Introduction

Cornual (Interstitial) pregnancy, is an ectopic pregnancy localized in the intramural part of the fallopian tube and covered by the myometrium. Although cornual pregnancies are rare – only 2-4% of ectopic pregnancies - their incidence is increasing (1, 2). The diagnosis and treatment may be challenging due to its anatomic localization. Early detection of cornual ectopic pregnancies has become possible with wide use of high-resolution transvaginal ultrasonography (TVUS) and the use of β -human chorionic gonadotropin (β -hCG) (1, 3). The detection can be as early as 6.8 to 8.8 weeks, but the clinician should have a high clinical suspicion (2, 3). Early diagnosis is the key to successful treatment and

positive outcomes in patients with interstitial pregnancy.

The uterus may be ruptured in 20% of the cases that exceed 12 weeks, and this may cause massive bleeding. The rate of maternal mortality due to cornual pregnancies is estimated to be 7 folds higher compared to overall mortality rate of ectopic pregnancies – estimated as 2.5% higher (1, 4). According to the reports published between 2000 and 2002, cornual pregnancy is a rare and hazardous condition. Again in the same reports, eleven maternal deaths have been reported with four being cornual ectopic pregnancies (5).

There are different options for the treatment of cornual pregnancy such as the expectant approach, medical and surgical management. Patients can be medically treated with direct injection of potassium

*Corresponding Author: Pınar Kadiroğulları, Kanuni Sultan Suleyman Research and Training Hospital, Department of Obstetrics and Gynecology, Istanbul/Turkey

E-mail: pinarsezer33@hotmail.com, Mobile: +90 (505) 494 72 35

Received: 12.07.2019, Accepted: 16.09.2019

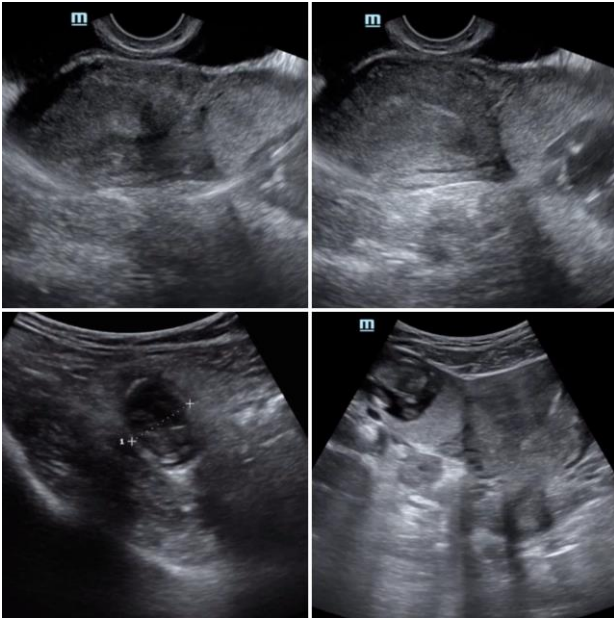


Fig. 1. Preoperative Ultrasonographic Image of the Case at 13 weeks 1 day among the Cases Diagnosed with Cornual Pregnancy

chloride (KCl), hypertonic solution and methotrexate into the gestational sac (6). It can also be surgically treated with cornual resection, cornuotomy or hysterectomy using laparotomy or laparoscopy. Finally, expectant approach can be preferred if the patient has no symptom and fetal mortality is confirmed with ultrasonography (6).

More than 300 laparoscopically managed pregnancy cases have been reported since 2000 (7). In general, when the diagnosis of ectopic pregnancy is made with laparoscopy, the operation can be converted to laparotomy after uncontrolled bleeding and wedge resection because of the difficulty in laparoscopic reconstruction of the cornual end. This is because of a few publications in the literature that discuss or summarize treatment methods in cornual pregnancies, or show the outcomes of laparoscopic treatment and subsequent pregnancies (8).

We plan mixed (local or systemic) medical treatment as the first choice for the treatment of this rare, but serious condition in our hospital, which is a tertiary center. However, if we consider surgery, we accept laparoscopic cornual resection and cornuotomy as the first choice as a surgical method in eligible patients. Herein, we aim to share our laparoscopic treatment option of 10 cornual ectopic pregnancies that we performed within the last 3 years.

Material and Methods

This study was designed as a retrospective evaluation of the perioperative clinical and laboratory data of the patients who underwent laparoscopic surgery

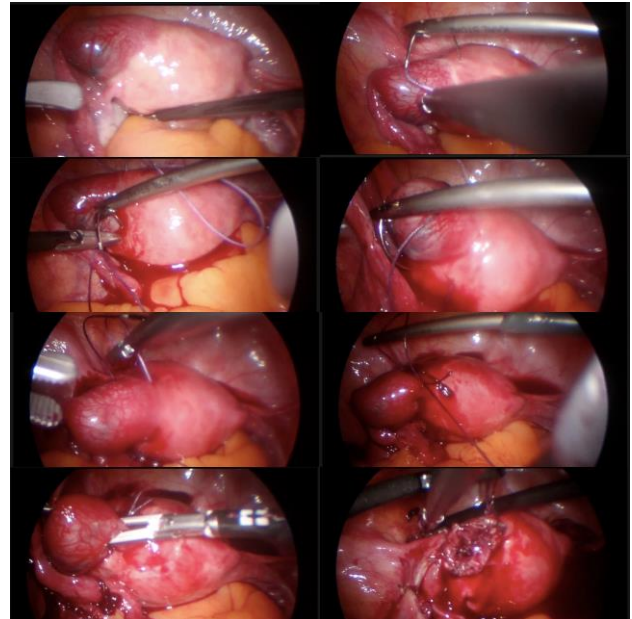


Fig. 2. Performed Surgical Steps; Laparoscopic Cornual Resection

approach due to cornual pregnancy in our gynecology and obstetrics clinic between January 2016 and January 2019. The study was recorded in the clinical.trial.gov with number NCT03974841. A total of 10 female patients who underwent laparoscopic cornual resection and cornuotomy due to cornual pregnancy were included in the study.

Patients' preoperative demographic data (age, gravida, parity etc.), complaints of admission, and predisposing factors were recorded. Gestational week at admission, pre- and postoperative 1st days hemoglobin (Hb) levels, length of hospital stay, and operation times were also recorded.

Three patients in whom it was decided to convert to laparotomy during the operation and treatment success could not be confirmed with β -hCG concentrations (lost from follow up) were excluded from the study. The diagnosis of cornual pregnancy was defined as a gestational sac separated from the most lateral wall of the uterine and seen as < 1 cm on ultrasonography (7) (Figure 1).

Laparoscopic surgery procedural steps were applied as specified in Figure 2 for laparoscopic cornual resection and Figure 3 for laparoscopic cornuotomy.

The patients were prepared in dorso-lithotomy position. After the surgical preparations, general anesthesia procedure was initiated. A 12 mm trocar was directly inserted in the umbilicus through a vertical skin incision. The abdomen was insufflated with CO₂. After confirming cornual pregnancy, three additional 5 mm auxiliary trocars were inserted in the left lower quadrant, right lower quadrant, and suprapubic area, respectively. Intra-abdominal

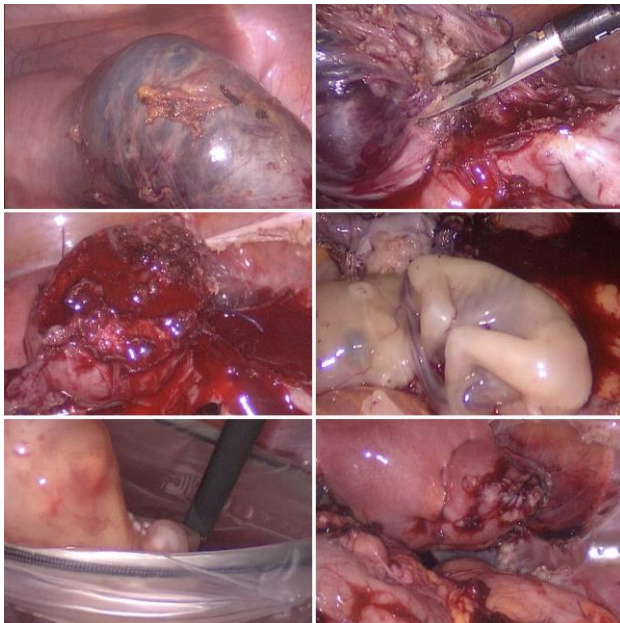


Fig. 3. Performed Surgical Steps; Laparoscopic Cornuotomy

pressure was kept at 12 mmHg during the operation. Around of the cornual pregnancy material was turned in circular form with Vicryl No:1 suture and ligated. A circumferential incision was then made at 1-2 cm above the cornual pregnancy basis using monopolar hook and harmonic scissors. Thus, serosal and myometrial tissues were left enough to close the uterus with minimal distortion. According to the discretion of the surgeon, laparoscopic cornual resection was performed regardless ipsilateral salpingectomy.

Again in the patients who underwent cornuotomy, around of the cornual pregnancy material was turned in circular form with Vicryl No:1 suture and ligated. Then monopolar laparoscopic hook was used to make an incision along the most swollen part of the cornual pregnancy. The pregnancy tissue was emptied with threaded forceps. The area in the incision was cleaned with an aspirator using high hydrostatic pressure.

In both techniques; double folds bed sutures were made with Vicryl No:1 in order to close myometrial defect with a configuration seen in Figure 8. Hemostasis was provided with suturing and bipolar cauterization was kept in minimum. The resection materials were removed using laparoscopic endobag. All patients were followed up once a week after discharge and

β -hCG levels were monitored until the end of the pregnancy.

The data were analyzed with IBM SPSS Statistics 20 for Macintosh package software. Normality of the continuous data was tested with Kolmogorov-

Smirnov method. Continuous variables are expressed as mean \pm standard deviation, and nominal variables as case number and percentage (%).

Results

A total of 10 cornual pregnancy cases were treated with laparoscopy during the study period, and the diagnosis was histopathologically confirmed in all patients. Three patients who underwent laparoscopic cornual resection were excluded from the study with two patients in whom it was decided to convert to laparoscopy and one patient whose treatment success could not be confirmed with β -hCG concentration after the surgery (lost from the follow up). Finally ten patients were evaluated.

The mean age of the patients was 29.5 \pm 4.0 (21-36) years. Clinical and demographic characteristics of the patients are seen in Table 1. Two (28.5%) patients had a history of previous tubal ectopic pregnancy. The mean gestational week was 7.40 \pm 2.36 (5-13) weeks. Three (42.7%) patients presented with pain and/or bleeding. Four patients (57.1%) had no symptoms, and cornual pregnancy was detected on routine control ultrasonography in these patients. The mean cornual pregnancy size was measured as 4.8 \pm 2.4 cm (2-8) on ultrasonography. Cornual pregnancy of 13 weeks 1 day with fetal heart beats was seen only in one patients according to ultrasonographic CRL measurement. The largest material was found as 8 cm in this patient. Five patients underwent cornual resection and two cornuotomy. The mean gravida of the patients who underwent cornuotomy was 1.6 \pm 0.8 and they had no living children. None of the patients developed rupture during surgical procedure. Simultaneous ipsilateral salpingectomy was performed in all patients who underwent laparoscopic cornual resection. Salpingectomy was not performed in any of the patients who underwent cornuotomy.

Uterus repair was carried out with suturing in all operated patients and no uterine anomaly was reported. Uterus was restored. The mean operational time was 64.5 \pm 22.6 (40-120) minutes. The operational time was measured as 51.6 \pm 12.8 minutes in the patients who underwent cornuotomy, and this was shorter compared to the patients who underwent cornual resection. The mean blood loss was 290 \pm 110 mL. Postoperative blood transfusion was performed only in one (1.1%) patient. Preoperative admission Hb of this patient was 7.7 g/dL. Pre- and postoperative 1st day Hb levels were 11.25 \pm 1.4 (7.7-13) g/dL and 10.13 \pm 1.37 (6.9-12.1) g/dL, respectively (Table 1). The mean preoperative β -hCG levels was 9258 \pm 9003 (2180-32000) IUI, and at follow up pregnancy was seen to be terminated in all patients. In

Table 1. Clinical and laboratory characteristics of patients who underwent cornual resection

Variables	Mean \pm SD (min –max)
Age	29.5 \pm 4.0 (21-36)
Gravidity	2.2 \pm 1.1 (1-4)
Parity	0.7 \pm 0.82 (0-2)
Gestational week at diagnosis (week \pm day)	7.40 \pm 2.36 (5-13)
Size of the corneal pregnancies (cm)	4.8 \pm 2.4 (2-8)
Predisposing factors	
Previous tubal ectopic pregnancy	2 (28.5%)
Previous pelvic inflammatory disease	2 (28.5%)
Previous pelvic surgery (Salpingectomy or tubal ligation, Cesarean section)	1 (14.2%)
Clinical complaints at admission	
Routine control	4 (57.1%)
Inguinal pain	2 (28.5%)
Abnormal bleeding	1 (14.2%)
Surgical outcomes	
Operation time (min)	64.5 \pm 22.6 (40-120)
Blood loss (mL)	290 \pm 110
Hb levels (g/dl) (preoperative)	11.25 \pm 1,4 (7,7-13)
Hb levels (g/dl) (postoperative 1st day)	10.13 \pm 1.37 (6.9-12.1)
Delta Hb value g/dl	1.19 \pm 0.57
Length of hospital stay (days)	2.7 \pm 0.67 (2-4)
β -hCG, IU/l	9258 \pm 9003 (2180-32000)

our series no major intraoperative surgical complication was seen. The mean length of hospital stay was 2.7 \pm 0.67 days.

Discussion

Diagnosis and treatment process is still unclear in cornual pregnancy. Although cornual pregnancy accounts for only 2-4% of ectopic pregnancies, it has a higher risk of morbidity and mortality compared to the tubal pregnancies (8). Ectopic pregnancies can be detected earlier than in the past with the existing developments in the diagnostic imaging and the use of β -hCG. Moawad et al. proposed that the diagnosis of a cornual pregnancy can be established in an early period such as 6.9 to 8.2 weeks with the use of a high clinical suspicion index together with understanding of characteristic risk factors and the use of TVUS (9). The patients in our study were diagnosed in mean 7.40 \pm 2.36 weeks, while the diagnosis was made with preoperative TVUS. Only in one patient the pregnancy progressed up to 13 weeks, and it was found that this patient did not present to the hospital

since the lack of symptoms and the diagnosis was established late.

Cornual pregnancy occurs in the interstitial part of the fallopian tube. This proximal part of the fallopian tube which has 0.7 mm width and 1-2 cm length is localized in the muscular wall of the uterus. Although myometrial distensibility tends to allow cornual pregnancy progression up to late weeks, in general uterine may be ruptured after a 8-week gestation. Early detection of cornual pregnancy has been historically difficult because of its anatomic location. It is quite difficult to distinguish this from an eccentric intrauterine pregnancy (10).

It has been reported that the rate of using transabdominal and transvaginal ultrasonography in order to determine gestational sac, which is seen less than 1 cm from the lateral edge of the uterine cavity, a thin myometrial layer surrounding the sac, and interstitial line mark has increased the rate of diagnosis (11). These criteria has 40% sensitivity and 88-93% specificity (9, 11). In addition, Ackerman et al. described the “interstitial line mark”, which is seen as an echogenic line extending along the endometrial cavity toward the cornual region on TVUS (12).

However, despite these recommended methods the diagnosis of cornual ectopic pregnancy remains a problem. In our study, the diagnosis of cornual pregnancy was made with preoperative ultrasonography in 5 of 7 (71.4%) patients. This rate was also reported as 71.4% in a series of 32 cornual pregnancies (2). According to our experience, laparoscopy is still a reliable diagnostic tool. In our study, we found that ectopic pregnancy cases that we considered as tubal were in fact originated from the uterine cornu in 2 of 10 patients. Although the preoperative diagnosis was ectopic pregnancy in our patients, we could not ensure that whether it was cornual until performing laparoscopy.

Traditionally, surgical treatment of cornual pregnancy has been cornual resection or hysterectomy with laparotomy. Medical treatment is preferred especially for asymptomatic patients who have desire for conception in the future and have no contraindications for methotrexate. However, surgery is an effective surgical option in cases of failed medical therapy, suspected cornual rupture, when compability of the patient is in question and cornual pregnancy is repeated (9). Another non-surgical option is direct injection of KCl or hypertonic solution into the gestational sac with the guidance of transvaginal ultrasonography (6). The main advantage of non-surgical treatment is rapid healing, minimal blood loss and shorter length of hospital stay, and this method is less invasive and inexpensive compared to the surgical option. However, there are some concerns with non-surgical treatment including cornual puncture related rupture massive bleeding (6). Another concern related to conservative treatment is relapse of ectopic pregnancy and especially recurrence of ipsilateral cornual pregnancy.

Endoscopic surgery has been applied in the treatment of cornual pregnancy for less than 10 years (3, 8). Hysteroscopy and laparoscopy are often used as surgical options. Laparoscopic techniques provide a more conservative approach in the treatment of cornual pregnancies. Therefore, recently some advocate conservative surgical treatment methods in order to better protect the integrity of the uterus to provide good fertility rates in future (8). In addition, surgical morbidity is lower and patient recovery is faster with laparoscopy. In general, laparoscopic techniques include cornual wedge resection, cornuotomy, and salpingectomy (8). Five of our patients were those undergone laparoscopic cornual resection and salpingectomy was added in these patients. Whereas cornuotomy was performed in two patients who have no living birth and planned conception in future. Before laparoscopy has become widespread, cornual wedge resection with laparotomy

was the gold standard for interstitial pregnancies (13). We believe that historical use of this technique has caused permanent popularity of cornual resection even in laparoscopic surgery age. Whereas laparoscopic cornuotomy is a relatively novel method using to remove the tissue without removing the myometrium that surrounds the cornual pregnancy material (13). Watanabe et al. (13 cases) and Wang et al. (38 cases) reported successful treatment outcomes of laparoscopic cornuotomy in relatively larger series (14, 15). Some surgeons prefer cornual resection especially in cases where the implantation is deep in the myometrium or the lesion size is relatively high.

Some surgeons agree on that size of the cornual pregnancy lesion is best determined with laparoscopic approach especially in case of deep implantation in the myometrium (16). Tulandi et al. reported that cornuotomy is the most appropriate for pregnancies < 3.5 cm, while Grobman and Milad (18) recommended cornual wedge resection for pregnancies > 4 cm. The main two concerns with the laparoscopic treatment of cornual pregnancy is recurrence in future pregnancies and the rupture of uterus. Tubal pathology is frequently stated as a primary factor for repeating cornual pregnancies. The etiology of repeating cornual pregnancy is not fully understood because of the recurrence even a good anatomic outcome is achieved (it was evaluated with hystesalpingography or laparoscopy) (19). The uterus may be ruptured in the next pregnancies following surgical procedures performed for cornual pregnancy (20). The predicted mechanism is predicted as a defective area in the uterus wall especially if endometrial cavity is also involved. Suturing repair performed to restoring and strengthen the defective area can reduce the risk of rupture (20). Another possible mechanism of uterine rupture is the tissue damage caused by electro-surgery during wedge resection and diathermy coagulation for hemostasis.

This study has several limitations. The cases that we included are evaluated only in postoperative early period. Again, although the number of patients we evaluated seems as a limitation, we believe that our results would shed light on the literature, because cornual ectopic pregnancy is extremely rare and, laparoscopic cornual resection and particularly cornuotomy are new trends in the surgical approach.

It is thought that carefully individualized prenatal care and planned cesarean section (37 weeks) is the most reliable approach in these cases for future pregnancies (9). It is recommended to perform TVUS in 5th to 6th gestational week in rule out recurrence of pregnancy in future (9,21). In general, the existing literature does not a clear guidance about optimal laparoscopic treatment and the risks of next fertilities.

In conclusion;

Cornual ectopic pregnancy is a rare type of pregnancy that is difficult to treat. Laparoscopic surgery of cornual pregnancies is an appropriate and safe treatment option. According to our experience, laparoscopic cornual resection or cornuotomy can be performed without unnecessary tissue dissection or causing trauma. It minimizes the general blood loss, enabling a blood free area for anatomical restoration, and thus preventing the risk of bleeding related morbidity and mortality. Laparoscopic treatment of cornual pregnancy can be performed safely with good outcomes by educated laparoscopic surgeons and in a center with sufficient facilities.

References

- Lau S, Tulandi T. Conservative medical and surgical management of interstitial ectopic pregnancy. *Fertil Steril* 1999; 72: 207-215.
- Tulandi T, Al-Jaroudi D. Interstitial pregnancy: results generated from the Society of Reproductive Surgeons Registry. *Obstet Gynecol* 2004; 103: 47-50.
- Soriano D, Vicus D, Mashiach R, et al. Laparoscopic treatment of cornual pregnancy: a series of 20 consecutive cases. *Fertil Steril* 2008; 90: 839-843.
- Walker JJ. Ectopic pregnancy. *Clin Obstet Gynecol* 2007; 50: 89-99.
- Lewis G, Drife J. Why Mothers Die 2000-2002. The Sixth Report of the Confidential Enquiries into Maternal Death in the United Kingdom. London, UK: RCOG Press; 2004.
- Myung JK, Yong WJ, Jae-Ho C, et al. Successful management of heterotopic cornual pregnancy with laparoscopic cornual resection. *European Journal of Obstetrics & Gynecology and Reproductive Biology* 2016; 203: 199-203.
- Cucinella G, Calagna G, Rotolo S, et al. Interstitial pregnancy: A 'Road Map' of surgical treatment based on a systematic review of the literature. *Gynecol Obstet Invest* 2014; 78: 141-149.
- Ng S, Hamontri S, Chua I, Chern B, Siow A. Laparoscopic management of 53 cases of cornual ectopic pregnancy. *Fertil Steril* 2009; 92: 448-452.
- Damario MA, Rock JA. Surgery for obstetrics: ectopic pregnancy. In: Te Linde RW, Rock JA, Jones HW, editors. *Te Linde's Operative Gynecology*. 9th ed. Philadelphia, PA: LippincottWilliams &Wilkins 2003; 798-824.
- Auslender R, Arodi J, Pascal B. Interstitial pregnancy: early diagnosis by ultrasonography. *Am J Obstet Gynecol* 1983; 15: 146: 717-718.
- Timor-Tritsch IE, Monteagudo A, Matera C, Veit CR. Sonographic evolution of cornual pregnancy treated without surgery. *Obstet Gynecol* 1992; 79: 1044-1049.
- Ackerman TE, Levi CS, Dashefsky SM, Holt SC, Lindsay DJ. An interstitial line: sonographic finding in an interstitial (cornual) ectopic pregnancy. *Radiology* 1993; 189: 83-87.
- Lee MH, Im SY, Kim MK, Shin SY, Park WI. The comparison of laparoscopic cornual resection and cornuotomy for interstitial pregnancy. *J Minim Invasive Gynecol* 2017; 24: 397-401.
- Wang J, Huang D, Lin X, et al. Incidence of interstitial pregnancy after in vitro fertilization/embryo transfer and the outcome of a consecutive series of 38 cases managed by laparoscopic cornuostomy or cornual repair. *J Minim Invasive Gynecol* 2016; 23: 739-747.
- Watanabe T, Watanabe Z, Watanabe T, Fujimoto K, Sasaki E. Laparoscopic cornuotomy for interstitial pregnancy and postoperative course. *J Obstet Gynaecol Res* 2014; 40: 1983-1988.
- Afifi Y, Mahmud A, Fatma A. Hemostatic Techniques for Laparoscopic Management of Cornual Pregnancy: Double-Impact Devascularization Technique. *J Minim Invasive Gynecol* 2016; 23: 274-280.
- Tulandi T, Vilos G, Gomel V. Laparoscopic treatment of interstitial pregnancy. *Obstet Gynecol* 1995; 85: 465.
- Grobman WA, Milad MP. Conservative management of a large corneal pregnancy. *Hum Reprod* 1998; 13: 2002-2024.
- Gleicher N, Karande V, Rabin D, Pratt D. Laparoscopic removal of twin cornual pregnancy after in vitro fertilization. *Fertil Steril* 1994; 61: 1161-1162.
- Weissman A, Fishman A. Uterine rupture after conservative surgery for interstitial pregnancy. *Eur J Obstet Gynecol Reprod Biol* 1992; 13: 237-239.
- Karaman E, Gülaç B, Karaman Y, Hendem DU, Han A. The Management of Cornual Ectopic Pregnancy: Two Case Reports. *İKSST Derg* 2014; 6: 49-53.