

# Ruptured Pulmonary Hydatid Cysts in The Course of Enteric Fever; An Unreported Case

Hanifi Yıldız<sup>1\*</sup>, Selami Ekin<sup>1</sup>, Ahmet Arısoy<sup>1</sup>, Hatice Beyazal Polat<sup>2</sup>, Fatma Beyazal Çeliker<sup>3</sup>

<sup>1</sup>Van Yüzüncü Yıl University Faculty of Medicine, Department of Pulmonary Diseases, Van, Turkey

<sup>2</sup>Recep Tayyip Erdoğan Üniversitesi, Tıp Fakültesi, İç Hastalıkları Ana Bilim Dalı, Rize, Türkiye

<sup>3</sup>Recep Tayyip Erdoğan Üniversitesi, Tıp Fakültesi, Radyoloji Ana Bilim Dalı, Rize, Türkiye

## ABSTRACT

A thirty-two-years-old female admitted to the emergency department of a peripheral hospital with complaints of fever, cough, nausea, vomiting, heartburn, and abdominal pain. An empiric treatment has been given to the patient. Three days later, the patient has been referred to the department of internal medicine through increased complaints and was diagnosed with reflux and enteric fever by esophagography and serology. After an evaluation requested from our clinic due to ground-glass-opacities and a cavitary-lesion observed on the radiography, a ruptured cystic-echinococcosis was considered. The diagnosis was confirmed by IHA-test and cystic-membranes detected on computed tomography (CT). The patient refused the surgical treatment and was followed up for three months with oral albendazole. On the CT, taken in the second month, there was not any pathology other than the old ruptured cyst. As a result, this case will be the first case of pulmonary hydatid cyst reported being ruptured in the course of enteric fever.

**Key Words:** Hydatid cysts, rupture, typhoid fever

## Introduction

Our country is an endemic region for both cystic echinococcosis and typhoid fever (1,2). The cystic echinococcosis is a parasitic disease caused by *E.granulosus*. It is widespread especially in the countries where the agriculture and animal husbandry are common (3,4). The liver (60%) and the lung (30%) are the most commonly affected organs by this disease. Patients with pulmonary cystic echinococcosis most often admit with the sputum, cough, and shortness of breath complaints, but rarely admit with hemoptysis (3-5). It has been reported that ruptured pulmonary cystic echinococcosis may be infected and it's clinical and radiologic features may mimic lung cancer and tuberculosis (3-5). Unless these complications were proven before the cyst had been ruptured, it can cause a misapprehension in diagnosis and treatment and even an unnecessary surgery such as pneumonectomy (3).

It has been reported that the cystic echinococcosis is very rarely infected with the brucellosis and salmonella in which case the clinical table may overlap and can mask each other (6,7). Patients with enteric fever may have symptoms of fever, fatigue, headache, anorexia, joint pains, abdominal

pain, vomiting, cough, diarrhea (8). Here, we will present the first case of pulmonary hydatid cyst that is ruptured in the course of enteric fever. Patient approval was obtained for this study.

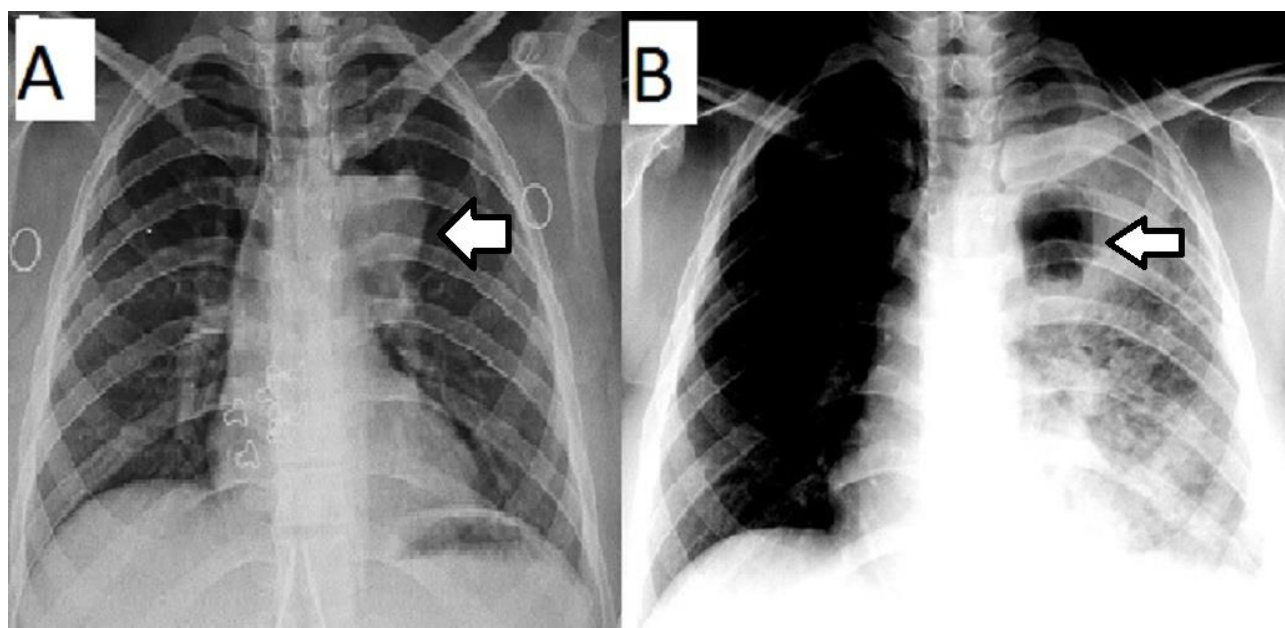
## Case Report

14th of June in 2013, a 32-year-old female patient was admitted to the emergency department of a peripheral hospital because of the complaints of abdominal pain, fever, cough, chest pain, nausea, vomiting, and heartburn starting for about five days. The first chest radiography had been assessed to be as normal. According to her complaints, an empiric treatment of respiratory tract infection and reflux has been given to the patient. Three days later, the patient has been referred to the department of our hospital internal medicine due to the increased complaints. The reflux was detected by barium esophagography. In the testing of tube agglutination (Gruber-Widal), H antigen was found to be 1/400, O antigen was found to be 1/100. The leukocyte count and CRP were measured as 4,300 mm<sup>3</sup> and 207 mg/dl respectively. According to the symptoms and laboratory tests, the patient has been diagnosed with enteric fever and reflux.

\*Corresponding Author: Hanifi Yıldız, Van Yüzüncü Yıl Üniversitesi Tıp Fakültesi, Türkiye Göğüs Hastalıkları Ana Bilim Dalı, Van, Türkiye,

E-mail: yhanifi1980@gmail.com, Phone: 0(507) 232 41 65

Received: 10.07.2018, Accepted: 20.09.2018



**Fig. 1.** Image A shows the first radiography taken at the peripheral hospital. White arrow shows the intact cyst. Image B shows a cavitary lesion, which is considered a ruptured hydatid cyst and infiltrates on the second radiography. White arrow shows the cavitary lesion (Ruptured cyst)

With suspicion of tuberculosis and pulmonary carcinoma, a consultation requested from our clinic by the department of internal medicine. After an evaluation, the lesion was considered to be a ruptured hydatid according to radiologic findings which are compatible with hydatid cyst such as ground-glass opacities, thick-walled, and air-containing cavitary lesion, observed in the left lung on radiography s(Figure 1). On physical examination, the patient's heart rate and respiration rate, blood pressure, oxygen saturation, and axillary fever were detected to be 130 beats/min and 25/min, 90/60 mmHg, 85%, and 38° Celsius, respectively. The breath sounds were diminished in the left lower bases of hemithorax. A pathogenic bacterium was not detected in the sputum culture. A tuberculosis bacillus was not detected in the acid-fast stain and malignant cytology was not observed in the cytological examination.

The patient was treated with the oxygen therapy with a flow of 2 Lt/min, 1 gram of ampicillin-sulbactam twice a day, 200 mg of ciprofloxacin twice daily, and H<sub>2</sub> receptor blocker once a day. Additionally, the patient was treated with 40 mg methylprednisolone a day for a possible anaphylactic reaction. A well-defined rounded nodular opacity located in the vicinity of the aortic arch on the left lung was noticed on the first chest radiograph taken at the peripheral hospital (Figure 1).

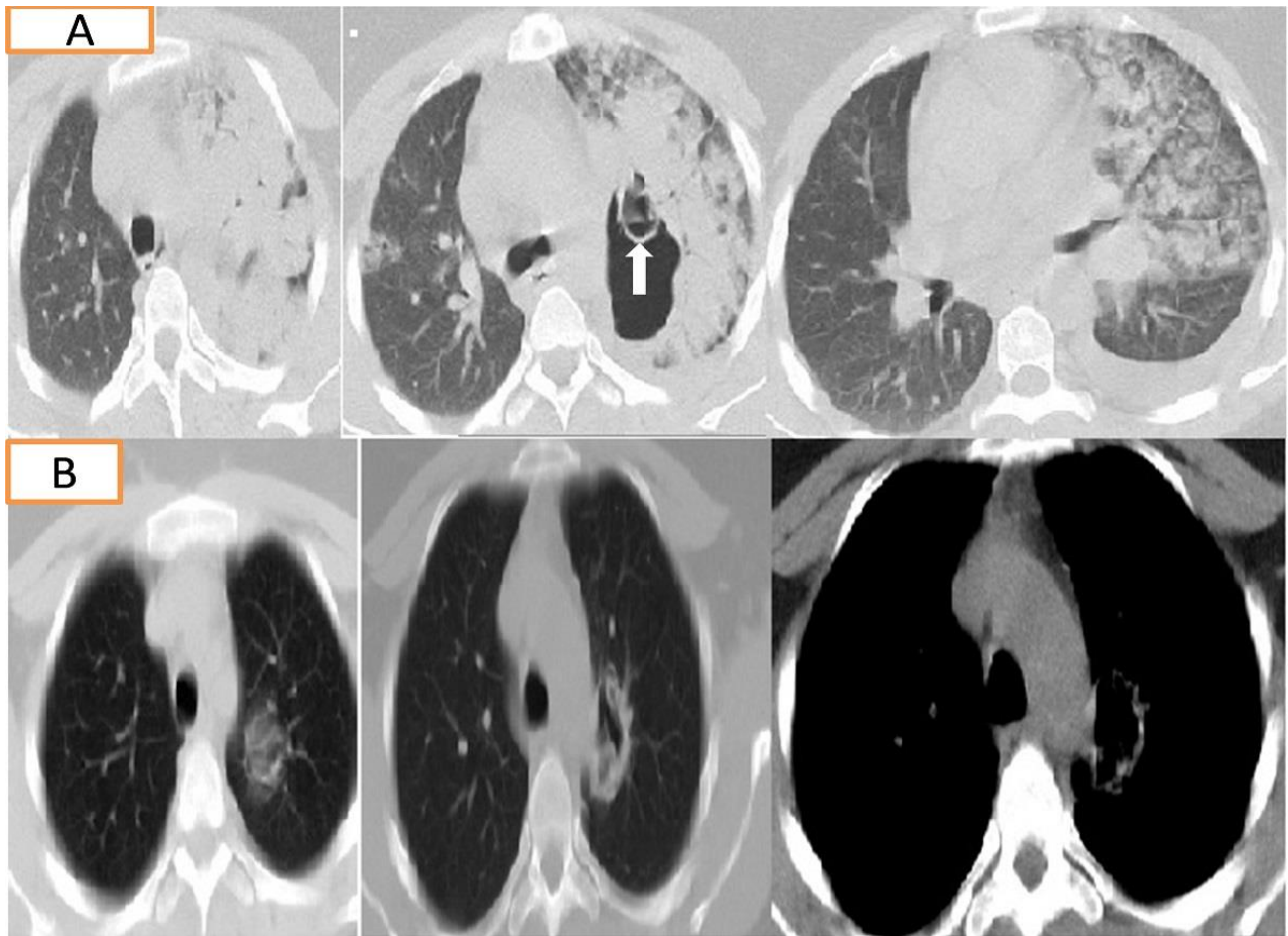
Therefore, we concluded that the hydatid cyst may have ruptured in the course of enteric fever

caused by increased intrathoracic pressure due to the reflux, cough, nausea, and vomiting. Specific antigen was found to be positive with 1/640 titer by indirect hemagglutination (IHA) test. The patient has received 400 treatment of albendazole with twice daily. Abdominal ultrasonography taken for possible hepatic involvement was evaluated to be normal.

The patient's temperature fell down on the third day of the treatment and the patient's complaints were decreased. H antigen fell to 1/100 and O antigen was detected as negative. The level of CRP was decreased to 19 mg/dl on the third day and to 5 mg/dl on the fifth day. On her control chest X-ray, the ground-glass opacities were significantly decreased. Patient refused the surgical treatment and was followed up for three months with oral albendazole. Two months later, no pathology was seen on CT images, except for ruptured an ancient cyst (Figure 2).

## Discussion

The rupture of pulmonary hydatid cysts is not a rare complication. Rupture can be both into the pleural space and into the bronchi (3). The complications associated with rupture of a cyst in to the pleural cavity are the pleural effusion, pleural thickening, lung extinction, simple or tension pneumothorax, bronchopleural fistula, remaining large cavity, and the infection leading to empyema (3,4). If the complications have not been proved before the rupture, the complications



**Fig. 2.** The figure shows the first and control thoracic-CT images. The images A show the first CT images taken during the rupture and white arrow shows germinal membranes, the images B show the second CT images taken at the second months

related to cyst rupture may cause misdiagnosis and even an unnecessary operation such as pneumonectomy (3-5).

The radiographic findings of the ruptured cysts may be rarely confused with the cavitary pulmonary tuberculosis as seen in our case (3-5). It has been reported that CT scan may provide a specific diagnosis of pulmonary hydatid cysts by showing the number and characteristics of cysts, characteristic features of complicated cysts, and secondary changes in neighboring structures (9). Whether there are characteristic signs or not, the demonstration of air-bubbles within the cyst, together with the widening ring, are robust cursor for infected hydatid cysts (9). Likewise, we used thoracic CT for the differential diagnosis of hydatid cyst. By CT images, we saw the air-bubbles within the cyst, together with a widening ring of the cyst and lamellar appearance belonging to the germinal membrane which is specific for hydatid cysts, as well. Additionally, there were no acid-resistant bacilli in the sputum microscope. The sensitivity of the IHA tests for diagnosis of pulmonary hydatid cysts has been reported to be

50-56% (10). The diagnosis of our patient was confirmed by IHA test and the CT imaging.

The treatment of cyst hydatid is primarily surgery. In addition to the surgery, as a medical treatment, the albendazole and its derivatives are used in patients who cannot tolerate and refuses the surgery or whose lesion cannot be removed by surgery (11). Likewise, our patient refused the surgical intervention and was followed up for three months by albendazole therapy. On CT and chest X-ray, taken after two months and one year later, there wasn't any pathology except for ancient the ruptured cyst. Although CT and immunological tests may be sufficient for diagnosis, the absence of surgical excision in our case, and therefore the inability to perform a histopathological evaluation of the cystic material, constitutes an incomplete direction of our study. It has been reported that intrapulmonary pressure increases during the expulsive phase of vomiting and exceeds atmospheric pressure because of transmission of increased intra-abdominal pressure (12). Additionally, the increased intra-abdominal pressure has been reported to be

played a role in the pathogenesis of reflux (13). This may explain the reflux and possible cyst rupture in the causal direction in our patient. In a comparative study, for the diagnosis of acid-reflux, the sensitivity of barium study was found to be 95% and an overall accuracy was found to be 86% (14).

Even if it is accepted as a standard in the diagnosis of typhoid fever, the culture is not easy to implement in daily practice (2). For this reason, symptoms and serological tests are used for enteric fever in daily practice (2). In serologically 'O' and 'H' antibodies increase after one week of the enteric fever course (2). It has been found that 1/200 and higher titers of H and O antibody showed a sensitivity of 90% with the cultures of typhoid patients. The sensitivity of H and O antibody increases especially after for 7 and 10 days in patients with typhoid fever (2). The serologic test results and barium-based esophagography findings suggest that an intact cyst may result in rupture due to the increased intrathoracic and intraabdominal pressure caused by the symptoms such as nausea, vomiting, cough, stomach pain and the chest pain which where occurred in the course of enteric fever. Furthermore, the increased pressure can cause acid-reflux during the enteric fever. We report this comorbidity and its results for the first time in the literature.

The patient who has previously received antibiotic therapy is unlikely to grove the paratyphoid bacteria in the cultures (15). When we transfer the case to our clinic, the patient was serologically in the second week of enteric fever. Additionally, the pathogenic bacteria were not detected in the sputum culture of our case. This may be seen due to the antibiotic treatment which has previously been given to the patient with suspicion of upper respiratory tract infection. Furthermore, in our serology, the presence of 100 and 400 titers of 'O' and 'H' antigens are compatible with the subacute paratyphoid period according to the literature (2).

In conclusion, with this rare case with enteric fever, we would like to emphasize that a present intact pulmonary hydatid cyst may rupture in patients with symptoms that cause the increase in the intrathoracic pressure, such as nausea, vomiting, coughing, and reflux.

## References

1. Kumar MJ, Toe K, Banerjee RD. Hydatid cyst of liver. *Postgrad Med J* 2003; 79: 113-114.

2. Willke A, Ergonul O, Bayar B. Widal test in diagnosis of typhoid fever in Turkey. *Clin Diagn Lab Immunol* 2002; 9: 938-941.
3. Balci AE, Eren N, Eren S, Ulku R. Ruptured hydatid cysts of the lung in children: clinical review and results of surgery. *The Annals of thoracic surgery* 2002; 74: 889-892.
4. Puri D, Mandal AK, Kaur HP, Mahant TS. Ruptured hydatid cyst with an unusual presentation. *Case reports in surgery* 2011; 2011: 730604.
5. Ozsurekci Y, Parlakay AO, Cengiz AB, et al. [Atypical presentation in hydatid disease: hemoptysis]. *Turkiye parazitoloji dergisi* 2013; 37: 64-68.
6. Arslan F, Zengin K, Mert A, Ozaras R, Tabak F. Pelvic and retroperitoneal hydatid cysts superinfected with *Brucella* sp and review of infected hydatid cysts. *Trop Biomed* 2013; 30: 92-96.
7. Aslam F, Bhaila I, Nadeem N, Fadoo Z. *Salmonella* typhi-infected lung hydatid cyst. *The Pediatric infectious disease journal* 2005; 24: 270-272.
8. Nsutebu EF, Martins P, Adiogo D. Prevalence of typhoid fever in febrile patients with symptoms clinically compatible with typhoid fever in Cameroon. *Tropical medicine&international health: TM&IH* 2003; 8: 575-578.
9. Kervancioglu R, Bayram M, Elbeyli L. CT findings in pulmonary hydatid disease. *Acta Radiol* 1999; 40: 510-514.
10. Di Comite G, Dognini G, Gaiera G, Ieri R, Praderio L. Acute echinococcosis: a case report. *Journal of clinical microbiology* 2000; 38: 4679-4680.
11. Moro P, Schantz PM. Echinococcosis: a review. *Int J Infect Dis* 2009; 13: 125-133.
12. Andrews PL. Physiology of nausea and vomiting. *British journal of anaesthesia* 1992; 69: 2S-19S.
13. Dodds WJ, Dent J, Hogan WJ, et al. Mechanisms of gastroesophageal reflux in patients with reflux esophagitis. *The New England journal of medicine* 1982; 307: 1547-1552.
14. Blumhagen JD, Christie DL. Gastroesophageal reflux in children: evaluation of the water siphon test. *Radiology* 1979; 131: 345-349.
15. Guerra-Caceres JG, Gotuzzo-Herencia E, Crosby-Dagnino E, Miro-Quesada M, Carrillo-Parodi C. Diagnostic value of bone marrow culture in typhoid fever. *Transactions of the Royal Society of Tropical Medicine and Hygiene* 1979; 73: 680-683.