








Improvement of SNOT-22 in Cured Antrochoanal Polyps

Ayşe Enise Göker , Berk Gürpınar , Güler Berkiten , Erdi Özdemir , Belgin Tutar , Ziya Saltürk , Yavuz Uyar 

Department of Otorhinolaryngology, Health Sciences University Okmeydanı Training and Research Hospital, İstanbul, Turkey

Abstract

Objective: Antrochoanal polyps (ACP) are unilateral nasal masses originating from the maxillary sinuses. We used the Sinonasal Outcome Test (SNOT-22) for determining the quality of life before and after ACP were excised via surgery.

Methods: Forty ACP were excised by a combination surgery of powered instrument and canine fossa catheterization. We measured and compared SNOT-22 levels before and one month after the surgery.

Results: A total of 22 male and 18 female subjects with unilateral ACP were included in the present study; 14 subjects were less than 20 years of age and the remaining subjects were between 15 and 68 years. The mean follow-up period was 34±20 months. No recurrence was observed in the follow-up period. The mean total preoperative SNOT-22 score was 50.61±19.21 and the mean postoperative SNOT-22 score was 16.80±10.75.

Conclusion: Combined powered surgery is a good alternative for ACP removal. Besides providing a clean surgical field, complete excision of the polyp prevents recurrences. This surgery significantly improved the quality of life, which was visible even after three years.

Keywords: Nasal polyps, nasal cavity, edema

ORCID IDs of the authors:

A.E.G. 0000-0002-9095-2237;
B.G. 0000-0002-6060-0791;
G.B. 0000-00021532-6113;
E.Ö. 0000-0002-4543-2494;
B.T. 0000-0001-7783-0908;
Z.S. 0000-0001-6722-7862;
Y.U. 0000-0001-8732-4208

Cite this article as:

Göker AE, Gürpınar B, Berkiten G, Özdemir E, Tutar B, Saltürk Z, et al. Improvement of SNOT-22 in cured antrochoanal polyps. Eur Arch Med Res 2018; 34 (4): 251-4.

Corresponding Author:

Ayşe Enise Göker

E-mail:

ayseenise@hotmail.com

Received: 17.05.2017

Accepted: 25.12.2017

DOI: 10.5152/eamr.2018.97059

Content of this journal is licensed under a Creative Commons Attribution-NonCommercial 4.0 International License.



INTRODUCTION

Antrochoanal polyps (ACP) is a unilateral, non-allergic obstructive nasal pathology. It generally originates from the maxillary antrum and reaches the nasal choana passing through the natural maxillary ostium. ACP has two components, the antral part is primarily cystic and the choanal part is solid (1). Although mostly unilateral, few cases of bilateral ACP have been reported. Diagnosis is made based on physical examination and computerized tomography (CT) findings; the polyp generally widens the ostium, fills the nasal cavity, and reaches the choana. No bone destruction is expected. Surgery is the choice of treatment as medical therapy offers no benefits. Throughout the years, a vast choice of surgical approaches have been described but the most popular one is the Caldwell-Luc+Endoscopic powered instrumental surgery of the sinus (2-4).

Sinonasal Outcome Test (SNOT) is a modification of the 31-question Rhinosinusitis Outcome Measure and has been developed with time. Previously, SNOT-20 has been used for patient outcomes, but lately SNOT-22 has been validated for impact of chronic rhinosinusitis on patients' quality of life and for the benefits of the surgery (5). In the present study, we aimed to compare the benefits of the surgery with the aid of a validated quality of life test to determine the results of combined powered sinus surgery.

METHODS

Study Subjects and Design

Between October 2011 and December 2016, 40 retrospective subjects were enrolled in the present study. The study protocol has been approved by the institutional review board of Okmeydanı Training and Research Hospital. All subjects underwent a thorough otolaryngologic examination

including nasal endoscopy. Routine blood tests, skin prick tests, computerized tomography of the sinuses, and thoracic examination against respiratory diseases have been performed for all

Table 1. Preoperative and Postoperative SNOT-22 values

SNOT-22	Preoperative	Postoperative	p
	Mean±SD (Median)	Mean±SD (Median)	
1. Need to blow nose	3.3±0.98 (3)	1.55±0.89 (2)	0.001*
2. Nasal Blockage	3.7±1.22 (4)	1.05±0.94 (1)	0.001*
3. Sneezing	2.05±1.57 (3)	1.55±1.64 (1)	0.155
4. Runny nose	3.3±1.26 (4)	1.35±0.88 (1)	0.001*
5. Cough	1.7±1.42 (2)	0.8±1.15 (0)	0.005*
6. Post-nasal discharge	3.4±1.19 (4)	1.4±1.19 (1)	0.001*
7. Thick nasal discharge	2.55±1.32 (3)	1.15±0.99 (1)	0.002*
8. Ear fullness	0.95±1.19 (1)	0.2±0.52 (0)	0.004*
9. Dizziness	0.35±0.93 (0)	0.1±0.45 (0)	0.102
10. Ear pain	0.7±1.03 (0)	0.15±0.49 (0)	0.014*
11. Facial pain/pressure	3.1±1.68 (4)	0.7±0.92 (0)	0.001*
12. Decreased Sense of Smell/Taste	3.5±1.7 (4)	0.6±0.82 (0)	0.001*
13. Difficulty falling asleep	3.05±1.54 (4)	0.7±0.73 (1)	0.001*
14. Wake up at night	2.75±1.45 (3)	0.65±0.59 (1)	0.001*
15. Lack of a good night's sleep	2.9±1.55 (4)	0.55±0.6 (0.5)	0.001*
16. Wake up tired	2.85±1.5 (4)	0.55±0.69 (0)	0.001*
17. Fatigue	2.95±1.39 (4)	0.7±0.66 (1)	0.001*
18. Reduced productivity	2.35±1.27 (3)	0.5±0.83 (0)	0.001*
19. Reduced concentration	2.3±1.38 (3)	0.5±0.76 (0)	0.001*
20. Frustrated/restless/irritable	2.5±1.99 (3)	1.75±1.77 (1)	0.058
21. Sad	0.45±1.23 (0)	0.15±0.49 (0)	0.18
22. Embarrassed	0.7±1.63 (0)	0.3±0.98 (0)	0.059

*statistically significant

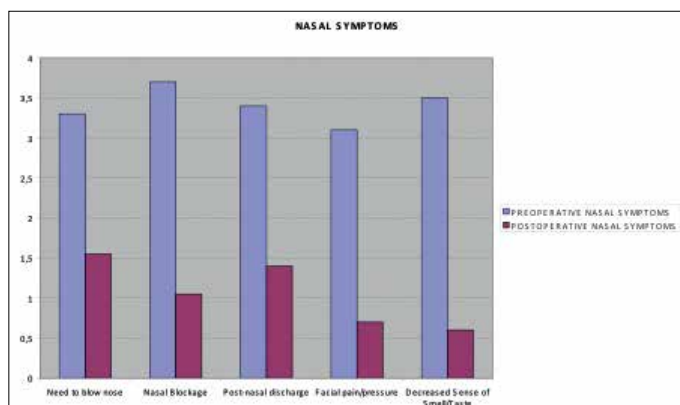


Figure 1. Pre-operative and Post-operative comparison of the most frequent five nasal symptoms

patients. Exclusion criteria included remarkable septal deviation and obstructive adenoids, positive respiratory allergens, nasal polyps other than ACP, and history/signs of asthma. The patients who were diagnosed with ACP, were mentioned detailed information and consent forms for all patients were taken.

Surgical Technique

All subjects were operated on under general anesthesia. As a standard protocol, each patient was placed in the supine position with the head slightly elevated. The nasal mucosa was shrunk and anesthetized using gauze strips impregnated with 0.1% xylometazoline hydrochloride and locally with Lidocaine HCL+Epinephrine mucosal injections. Initially, the intranasal portion of ACP was removed. Using a back-biting forceps, the back portion of the uncinate process was removed and the cutter blade (Stryker instruments, MI) of powered instrumentation was introduced to widen the maxillary ostium. A 4-mm, 30° endoscope was then inserted into the maxillary sinus to examine the antral floor through a trocar with a cannula, inserted sublabially into the maxillary sinus through the canine fossa. Lastly, antibiotic ointment (mupirocin 2%) was applied to the sinus mucosa and nasal packs were placed in the nasal cavity for one day. Oral antibiotic (amoxicillin-clavulonate 1000 mg BID) is administered for 2 weeks. All patients were followed up on a weekly basis for the first month, thereafter once in every month for three months for the first year, and then once every year. At every visit, each patient was questioned about a change in the SNOT-22 parameters.

SNOT-22

All subjects received SNOT-22 test for evaluation and benefits of the surgery. Each question was scored from 0 (no problem) to 5 (worst of symptoms). Initially, all raw data is gathered, examined and statistically investigated to compare the pre-and post-operative quality of life. Secondly, sinonasal scores of the test is determined by picking up the most frequent five nasal problems.

Statistical Analysis

Statistical analysis were performed using Statistical Package for Social Sciences version 22.0 (IBM SPSS Corp.; Armonk, NY, USA) Continuous data is displayed as mean±standard deviation. Statistical significance is accepted at $p < 0.05$. Wilcoxon and Mann Whitney U tests were used to determine statistically significant variances.

RESULTS

In the present study, 40 subjects were enrolled. Twenty-two subjects (55%) were men and 18 (45%) were women, and 14 subjects were aged less than 20 years and the remaining subjects were between 15 and 68 years (mean 24 and 37 years). All polyps were unilateral (21 left, 19 right-sided).

The mean follow-up period was 34 ± 20 months. No recurrence was observed in the follow-up period.

The mean total pre-operative SNOT-22 score (of all 22 items) was 50.61 ± 19.21 and the mean post-operative SNOT-22 score was 16.80 ± 10.75 . The difference was statistically significant ($p < 0.005$) (Table 1). Pre-and post-operative comparison of the most frequently occurring five nasal problems are shown as a graphic (Figure 1). No significant change is observed in the post-operative SNOT-22 parameters during the follow-up period.

DISCUSSION

Antrochoanal polyps do not have a certain etiopathogenesis. Chronic sinusitis and allergic rhinitis are suspected as the etiological factors. Nasal mucosa, particularly in the region of middle meatus, becomes oedematous because of the collection of extracellular fluid causing polypoidal change. Polyps that are sessile in the beginning become pedunculated due to gravity and sneezing. In early stages, the surface of nasal polyp is covered by ciliated columnar epithelium, but it later undergoes metaplastic change to squamous type on atmospheric irritation. Submucosa shows large intercellular spaces filled with serous fluid. The medial aspect of the cyst obstructs both the accessory and the natural maxillary ostium and the trapped air and high pressure in the maxillary sinus force the mucous retention cysts to herniate into the nasal cavity (6-8).

The disease is primarily observed in children and adolescents, but the published data reports cases of patients between the ages of 5 and 81 years. Chief complaints include nasal obstruction in 100%, rhinorrhea in 48% and snoring in 36% of ACP cases and minor complaints are headache, epistaxis, hiposmia, sneezing, dyspnea, halitosis, and dysphonia. Cachexia and sleep apnea caused by ACP are also reported in the literature (8). The subjects in this study were generally young adults who experienced all the aforementioned symptoms; additionally, they also felt pain and pressure in the face.

Medical therapy is widely considered as a nonviable treatment option for ACP. Endoscopic sinus surgery (ESS), Caldwell-Luc procedure, simple polypectomy, transcanine sinuscopy are being used. Simple polypectomy has the highest recurrence rates up to 25% and recurrence is the main problem after surgery (9).

Endoscopic sinus surgery is the current approach, but non-powered surgical appliances may not provide a bloodless surgical field, so inadequate removal of the polyp may result in recurrence. Anterior and inferior parts of the maxillary sinus are hard-to-reach areas; therefore, conventional endoscopic sinus surgery is inadequate to completely remove the ACP (9). Balıkcı et al. (9) used ESC in 31 cases of ACP and 2 showed recurrence, while Kamel et al. (10) and Cook et al. (11) reported no recurrence using the same method. Combined approaches such as ESC+Caldwell-Luc and ESC+Transcanine antrostomy have a better visual operative field so they may lower the recurrence rates. Ozer et al. (12) had three recurrences with ESC, but none with ESC+Caldwell-Luc or transcanine sinuscopy. We also preferred powered ESC+Transcanine approach for a clear visual field adequate to remove all the polyps to prevent recurrence. Our aim was to reach the inferior and anterior parts of the maxillary sinus and to completely remove ACP. No single method is able to visualize the entire maxillary sinus; this combination takes longer but prevents recurrence.

Chaiyasate et al. (13) reported that 95% of recurrence is noted in the first two years post-operatively and recurrence is significantly higher in children. Our follow-up period was long enough to cover a vast majority of recurrence. We noted no recurrence in the follow-up period.

Quality of life is the general well-being of individuals and societies, outlining negative and positive features of life. It observes life satisfaction, including everything from physical health, family, education, employment, wealth, religious beliefs, and finance to the environment. SNOT-22 is an increasingly popular tool to describe patient burden and clinical effectiveness in sinonasal disease. It covers a broad range of health and health-related quality-of-life problems including physical problems, functional limitations, and emotional consequences. Browne et al. (14) tested SNOT to make it more clinically meaningful and they suggested the use of SNOT as the following four subscales: impact of rhinological symptoms, ear and facial symptoms, psychological issues, and sleep functioning. To the best of our knowledge, no research has yet assessed the quality of life in ACP patients before and after surgery. The ACP patients on this study had both rhinological and facial symptoms but they reported no psychological or sleep issues. Therefore, our research seems to have appropriate results to assess rhinological outcomes of the pre-and post-operative quality of life for ACP. Furthermore, we chose rhinologic results of the test and scaled them. We believe that this will help in the identification of the benefits of the ACP surgery more clearly.

CONCLUSION

Antrochoanal polyps (ACP) arise from the maxillary sinus and herniate into the nasal cavity. Combined ESC and transcanine approach shows no recurrence and the quality of life significantly improves after the surgery.

Ethics Committee Approval: Ethics committee approval was received for this study from the ethics committee of Okmeydanı Training and Research Hospital (Decision Date: 23/02/2016/Decision No: 424).

Informed Consent: Written informed consent was obtained from the patients who participated in this study.

Peer-review: Externally peer-reviewed.

Author Contributions: Concept - A.E.G., E.O.; Design - G.B.; Supervision - Y.U, Z.S.; Data Collection and/or Processing - A.E.G, E.Ö.; Analysis and/or Interpretation - A.E.G, G.B, Z.S.; Literature Search - B.G.; Writing Manuscript - B.G.; Critical Review - B.G., G.B.

Conflict of Interest: The authors have no conflicts of interest to declare.

Financial Disclosure: The authors declared that this study has received no financial support.

REFERENCES

1. Frosini P, Picarella G, De Campora E. Antrochoanal polyp: analysis of 200 cases. *Acta Otorhinolaryngol Ital* 2009; 29: 21-6.
2. Basu SK, Bandyopadhyay SN, Bora H. Bilateral antrochoanal polyps. *J Laryngol Otol* 2001; 115: 561-2. [\[CrossRef\]](#)
3. Yuca K, Bayram I, Kiroglu AF, Etlik O, Cankaya H, Sakin F, et al. Evaluation and treatment of antrochoanal polyps. *J Otolaryngol* 2006; 35: 420-3. [\[CrossRef\]](#)
4. Gendeh BS, Long YT, Misiran K. Antrochoanal polyps: clinical presentation and the role of powered endoscopic polypectomy. *Asian J Surg* 2004; 27: 22-5. [\[CrossRef\]](#)

5. Hopkins C, Gillett S, Slack R, Lund VJ, Browne JP. Psychometric validity of the 22-item sinonasal outcome test. *Clin Otolaryngol* 2009; 34: 447-54. [\[CrossRef\]](#)
6. Onerci TM, Ferguson BJ, editors. Pathogenesis, Medical and Surgical Treatment. *Nasal Polyposis*; 2010.
7. Ozcan C, Zeren H, Talas DU, Kucukoglu M, Gorur K. Antrochoanal polyp: a transmission electron and light microscopic study. *Eur Arch Otorhinolaryngol* 2005; 262: 55-60. [\[CrossRef\]](#)
8. Atighechi S, Baradaranfar MH, Karimi G, Jafari R. Antrochoanal polyp: a comparative study of endoscopic endonasal surgery alone and endoscopic endonasal plus mini-Caldwell technique. *Eur Arch Otorhinolaryngol* 2009; 266: 1245-8. [\[CrossRef\]](#)
9. Balikci HH, Ozkul MH, Uvacin O, Yasar H, Karakas M, Gurdal M. Antrochoanal polyposis: analysis of 34 cases. *Eur Arch Otorhinolaryngol* 2013; 270:1651-4. [\[CrossRef\]](#)
10. Kamel R. Endoscopic transnasal surgery in antrochoanal polyps. *Arch Otolaryngol Head Neck Surg* 1990; 116: 841-3. [\[CrossRef\]](#)
11. Cook PR, Davis WE, McDonald R, McKinsey JP. Antrochoanal polyposis: A review of 33 cases. *Ear Nose Throat J* 1993; 72: 401-12.
12. Ozer F, Ozer C, Cagici CA, Canbolat T, Yilmazer C, Akkuzu B. Surgical approaches for antrochoanal polyp: a comparative analysis. *B-ENT* 2008; 4: 93-9.
13. Chaiyasate S, Roongrotwattanasiri K, Patumanond J, Fooanant S. Antrochoanal Polyps: How Long Should Follow-up be After Surgery? *Int J Otolaryngol* 2015; 1-5. [\[CrossRef\]](#)
14. Browne JP, Hopkins C, Slack R, Cano SJ. The Sino-Nasal Outcome Test (SNOT): Can we make it more clinically meaningful? *Otolaryngol Head Neck Surg* 2007; 136: 736-41. [\[CrossRef\]](#)