

Evaluation of myocardial function in pediatric patients with transposition of great arteries after arterial switch operation

Taliha Öner, Rahmi Özdemir, Barış Güven, Murat Muhtar Yilmazer, Önder Doksöz, Timur Meşe, Vedide Tavlı¹

Department of Pediatric Cardiology, İzmir Dr. Behçet Uz Children Hospital; İzmir-Turkey

¹Department of Pediatric Cardiology, Faculty of Medicine, Şifa University; İzmir-Turkey

ABSTRACT

Objective: An arterial switch operation converts the left ventricle (LV) into the systemic ventricle, replacing the right ventricle (RV), which is the systemic ventricle during the prenatal period. The procedure is performed in patients with arterial transposition and those in whom a coronary reimplantation procedure is performed. Therefore, the adaptation of LV and RV to the arterial switch operations is an interesting issue. This study aimed to evaluate systolic and diastolic functions in the LV and RV myocardium using echocardiography in pediatric patients with transposed great arteries after an arterial switch operation.

Methods: This observational case control study included 28 patients and 20 gender-and age-matched healthy controls. A group study was performed using patients who were followed for at least 6 months after the operation and who visited the pediatric cardiology outpatient between October 2009 and May 2011. Systolic and diastolic parameters, LV and RV myocardial performance index (MPI) values, and left atrium (LA) volume index were assessed in both groups.

Results: The LV MPI and tricuspid valve (TV) E/Ea ratio measured using pulsed-wave Doppler were higher in the patient group than in the control group. The TV E/A ratio and late velocity of lateral mitral annulus (Aa) and systolic velocity (Sa)-early diastolic velocity (Ea)-late velocity (Aa) of the septal mitral annulus and systolic velocity (Sa)-early diastolic velocity (Ea)-late velocity (Aa) of the lateral tricuspid annulus were lower in the patient group than in the control group.

Conclusion: Considering the present study's findings obtained during short-to mid-term follow-up, the RV tissue Doppler flows and the LV MPI were found impaired. (*Anatol J Cardiol* 2016; 16: 55-61)

Keywords: dextro-transposition of the great arteries, right ventricular dysfunction, myocardial ischemia, Doppler echocardiography

Introduction

Complete transposition of the great arteries (TGA) is the most common cyanotic heart disease in newborns and infants accounting for 5%-7% of all congenital heart diseases and occurring in 1/2100 to 1/4500 births (1). After Jatene et al. (2) described first the arterial switch operation (ASO) in 1975, the procedure rapidly replaced ASO as the preferred surgical operation for children with TGA without severe pulmonary stenosis. It was hoped that using the morphological left ventricle as the systemic ventricle would decrease the incidence of arrhythmias, atrioventricular valve dysfunction, and systemic ventricular failure compared with those observed during the late postoperative course of the atrial switch procedure (3, 4). Since the

initial introduction of the arterial switch surgery, cardiac surgeons have developed several modifications. Khairy et al. (5) developed a procedure to decrease the possibility of pulmonary tract stenosis. Although the long-term results of the ASO procedure are acceptable, several complications remain including pulmonary artery and branchial stenosis, reduced chronotropic response, coronary artery disease, neo-aortic stenosis, and regurgitation (5). Myocardial function after ASO has also been examined. For example, left ventricular myocardial function was evaluated using M-mode and tissue Doppler imaging (TDI), and the strain rate was analyzed using echocardiography and cardiac magnetic resonance imaging (MRI). However, only a very limited number of studies have evaluated both the right and left ventricular myocardium.

Address for Correspondence: Dr. Rahmi Özdemir, İzmir Dr. Behçet Uz Çocuk Hastanesi, Pediatrik Kardiyoloji Bölümü, 1374 St. No:11 Alsancak/İzmir-Türkiye
Phone: +90 232 489 56 56 E-mail: dr_ozdemir@hotmail.com

Accepted Date: 14.01.2015 **Available Online Date:** 11.02.2015

© Copyright 2016 by Turkish Society of Cardiology - Available online at www.anatoljcardiol.com
DOI:10.5152/akd.2015.5692



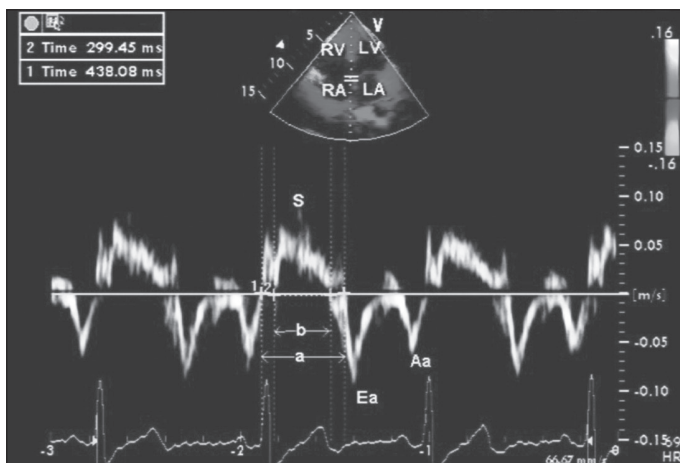


Figure 1. TDI measurements of the septal mitral annulus

Assessing the peak systolic velocities of both the left ventricle (LV) and right ventricle (RV) using TDI is a significant improvement over conventional echocardiography in assessing global and regional ventricular performance in various clinical conditions (6-10). Furthermore, evaluating the temporal occurrence of peak systolic velocities using TDI provides insights into electromechanical coupling and mechanical dyssynchrony (11). The myocardial performance index (MPI) is correlated significantly with the New York Heart Association (NYHA) class, ejection fraction (EF), and ventricular volumes. MPI is a Doppler-derived index of combined systolic and diastolic function, and many studies have recommended its use during the follow-up of cardiac patients. TDI and MPI also provide useful information regarding early myocardial function (12). The aim of the present study was to evaluate the right and left ventricular myocardial functions of patients with TGA after ASO during short-to mid-term follow-up using TDI and MPI.

Methods

This observational case-control study included 28 patients aged ≥ 6 months (range, 6–168 months) who underwent ASO. The study group included patients who were followed for at least 6 months after the operation and who visited the Pediatric Cardiology outpatient Izmir Dr. Behçet Uz Children's Hospital between October 2009 and May 2011. Age and gender-matched twenty non-anemic healthy subjects were enrolled as the control group. Systolic and diastolic parameters, TDI measurements, transthoracic echocardiography, and left and right ventricular MPI values were assessed in both groups. Additionally, coronary artery patterns and other concomitant abnormalities were recorded in the study group. Only two patients had been using an angiotensin-converting enzyme inhibitor. The study was approved by the Ethics Committee of our Institution.

Echocardiography

Transthoracic two-dimensional (2D) and Doppler echocardiographic examinations of the subjects were performed using a

GE Vivid 3 system (GE Healthcare, Milwaukee, WI, USA) with 3S and 7S transducers. M-mode echocardiographic measurements were obtained from left ventricular short-axis views at the level of the papillary muscles according to the recommendations of the American Society of Echocardiography (13-15).

Standard pulsed-wave Doppler echocardiography

The maximum velocities during apical four-chamber imaging were recorded using pulsed-wave (PW) Doppler with the sample volume placed at the mitral and tricuspid valve tips. The peak E (early fast-filling phase, passive filling) and peak A (atrial contraction phase, late active filling) velocities were measured using digital Doppler spectral analysis.

Tissue Doppler imaging

A 3 MHz transducer and a tissue Doppler imaging program were used. The sample volume was set at 2-4 mm. The Nyquist limit was set to 15–20 cm/s^{-1} , and the gain was set so that the noise would be minimal and the obtained tissue signals would be clear. For the apical four-chamber view, the sample volume was placed at the lateral mitral annulus, mitral septal annulus, and lateral tricuspid annulus. Recordings were then obtained for ≥ 5 cardiac cycles while the participants were relaxed, ensuring that flow was not be affected by respiration.

The peak early (Ea), late diastolic (Aa), and peak systolic (Sa) waves were recorded from the lateral mitral annulus, mitral septal annulus (Fig. 1), and lateral tricuspid annulus. The isovolumic contraction time (IVCT) was defined as the interval between the end of the Aa wave and the onset of the Sa wave. The isovolumic relaxation time (IVRT) was defined as the period from the end of the Sa wave to the onset of the Ea wave, and the ejection time (ET) was defined as the interval between the onset and end of the Sa wave (16). The E/Ea ratio was also measured to predict the left ventricular filling pressure (17).

Myocardial performance index

The myocardial performance index (MPI) was calculated from PW Doppler echocardiography either as the sum of IVCT and IVRT divided by ET or by subtracting the left ventricular ET from the time between the end and onset of mitral flow for LV and then dividing the result by ET (18).

Aortic regurgitation grading: Aortic regurgitation was graded as follows: absent, no flow with color Doppler; mild, the vena contracta of the regurgitant flow was 1-3 mm; moderate, the vena contracta of the regurgitant flow was 4-6 mm; severe, the vena contracta of the regurgitant flow was >6 mm (19).

Pulmonary stenosis grading: The measured pressure gradient for pulmonary stenosis in the present study was as follows: insignificant, <20 mm Hg; mild, 20-40 mm Hg; moderate, 40-60 mm Hg; severe, >60 mm Hg (20).

Table 1. Demographic characteristics of the two groups

Variable	Study group (n=28)	Control group (n=20)	P
Age, months	42.7±35	39.1±40.8	NS
Height, cm	94.5±22.19	92.1±23.6	NS
Weight, kg	15.3±8.4	15.2±11.3	NS
BSA, m ²	0.61±0.24	0.60±0.28	NS
BSA - body surface area; NS - not significant Values are expressed as mean ± SD. p values were calculated by Student-t test			

Table 2. Conventional echocardiographic and M-mode measurements in the study and control groups

Variable	Study group (n=28)	Control group (n=20)	P
LVEDd, cm	3.04±0.6	2.7±0.6	NS
LVESd, cm	1.8±0.4	1.69±0.3	NS
IVSd, cm	0.58±0.12	0.53±0.11	NS
IVSs, cm	0.9±0.2	0.87±0.19	NS
LVPWD, cm	0.85±0.2	0.88±0.2	NS
EF, %	71±5	70±5	NS
FS, %	39.5±4	39±4	NS
Left atrial volume index, mL/m ²	11.6±4	11.3±3.1	NS
Left ventricle mass index, g/cm ²	58.2±18.2	53.3±13.3	NS
EF - ejection fraction; FS - fractional shortening; IVSd - diastolic interventricular septum thickness; LVEDd - left ventricular end-diastolic diameter; LVESd - left ventricular end-systolic diameter; LVPWD - diastolic left ventricular posterior wall thickness; NS - not significant Values are expressed as mean ± SD. p values were calculated by Student t test			

Table 3. Pulse wave Doppler echocardiographic measurements in the two groups

Variable	Study group (n=28)	Control group (n=20)	P
Mitral valve			
E, m/s	1.07±0.15	1.05±0.15	NS
A, m/s	0.7±0.12	0.68±0.11	NS
E/A	1.5±0.3	1.5±0.3	NS
MPI	0.39±0.05	0.32±0.03	<0.001
Tricuspid valve			
E, m/s	0.79±0.1	0.71±0.1	0.023
A, m/s	0.68±0.1	0.52±0.08	<0.001
E/A	1.12±0.18	1.36±0.2	<0.001
MPI	0.26±0.5	0.24±0.4	NS
A - peak late-filling velocity measured using PW; E - peak early-filling velocity measured using PW; Ea - early-diastolic flow velocity in tissue Doppler; MPI - myocardial performance index; NS - not significant Values are expressed as mean ± SD. p values were calculated by Student-t test			

Left atrial volume: The oval/ellipse method was used to measure the left atrial volume. The left atrial diameter was determined based on sections of the apical four-chamber and para-

sternal long-axis. The formula $D1 \times D2 \times D3 \times 0.523$ was used, where D1, D2, and D3 are the transverse, longitudinal, and parasternal long-axes, respectively (21).

LV mass: The mass of the left ventricle was calculated using the following formula derived by Devereux et al. (22):

$$LV\text{mass} = 0.8[1.04(\text{interventricular septum thickness} + \text{posterior wall thickness} + \text{left ventricular end-diastolic diameter})^3 - (\text{LV end-diastolic diameter})^3] + 0.6.$$

Statistical analysis

Statistical analyses were performed using the Statistical Package for Social Sciences version 17 (SPSS, Inc., Chicago, IL, USA). All continuous variables were tested for normal distribution using Kolmogorov-Smirnov tests. The presence of differences between the control and patient groups was examined using *t*-tests for normally distributed data and Mann-Whitney U tests for data that were not normally distributed. *p*<0.05 was considered to be statistically significant.

Results

The study included 28 patients (75% males) in the study group and 20 age-, weight-, and height-matched subjects in the control group. The demographic data of the two groups are summarized in Table 1. Patient growth and development were within the normal limits, and none had signs of heart failure. All patients had undergone ASO; two-stage ASO was not performed in any of the patients. Only two patients underwent balloon atrial septostomy (BAS) before ASO.

The mean age at the time of surgery was 16.2±49 days (range, 2-270 days). The mean cardiopulmonary bypass (CPB) time was 134.1±25.2 min (range, 48-174 min), and the mean aortic cross-clamp time was 98.6±19.5 min (range, 38-129 min). Seventeen patients (60%) had normal coronary patterns, whereas 11 (39.3%) had coronary abnormalities. The most common coronary abnormality was the origination of the right coronary artery and left circumflex artery from sinus two and the left anterior descending artery from sinus one. Among the patient group, 46.4% had no additional cardiac anomalies, whereas six (21.4%) had restrictive ventricular septal defects (VSDs), and nine (32.1%) had non-restrictive VSDs that was closed using a patch during the surgical procedure. Two patients (7.1%) had dextrocardia, and one (3.5%) had persistent left superior vena cava. Additionally, 17 patients (60.7%) had aortic regurgitation (moderate regurgitation in one patient, severe regurgitation in one, and mild regurgitation in 15), and seven patients (25%) had supravalvular pulmonary stenosis (severe, moderate, and mild in two, one, and four patients, respectively).

There were no significant differences between the study and control groups regarding the 2D and M-mode measurements (Table 2). The PW Doppler echocardiographic measurements of the two groups are summarized in Table 3. There were

Table 4. Tissue Doppler imaging measurements of the two groups

Variable	Study group (n=28)	Control group (n=20)	P
Mitral lateral annulus			
Sa, cm/s	7.99±1.35	8.30±1.89	NS*
Ea, cm/s	15.86±2.97	15.85±2.83	NS [†]
Aa, cm/s	5.61±1.31	7.70±1.78	<0.001 [†]
E/Ea	7±1.7	6.7±1.5	NS [†]
Mitral septal annulus			
Sa, cm/s	4.46±0.69	6.30±1.17	<0.001*
Ea, cm/s	9.21±1.22	10.45±1.43	0.002 [†]
Aa, cm/s	4.32±0.90	5.30±0.92	0.001 [†]
Tricuspid lateral annulus			
Sa, cm/s	7.65±1.41	12.80±1.82	0.001 [†]
Ea, cm/s	12.07±2.03	16.55±2.35	<0.001 [†]
Aa, cm/s	6.54±1.57	10.45±1.39	<0.001 [†]
E/Ea	6.7±1.5	4.3±0.6	<0.001 [†]
Aa - peak velocity during atrial contraction; E - peak early-diastolic flow velocity; Ea - annular tissue Doppler component during early-diastole; NS - not significant; Sa - peak velocity during ventricular systole Values are expressed as mean ± SD. * : p were calculated by Mann Whitney U test † : p were calculated by Student-t test			

no significant differences in the peak E and A waves and E/A ratios obtained from the mitral valve ($p>0.05$). However, the tricuspid valve E/A ratio was significantly lower in the study group compared with the control group ($p<0.05$). The right ventricular MPI did not differ between the patient and control groups, whereas the left ventricular MPI was significantly higher in the study group. A comparison of the TDI data between the two groups is summarized in Table 4. Aa of the lateral mitral annulus and Sa, Ea, and Aa of the septal mitral annulus were lower in the patient group compared with the control group. The lateral tricuspid annulus Sa, Ea, and Aa wave velocities were significantly lower, and the tricuspid valve E/Ea ratio was significantly higher in the patient group compared with the control group ($p<0.05$).

Discussion

The right ventricular conventional Doppler flows, tissue Doppler flows, and left ventricular MPI were impaired during the short-to mid-term follow-up of the pediatric patients who underwent ASO in the current study. These findings suggest that pediatric patients with transposed great arteries after ASO had impaired ventricular function, particularly right ventricular diastolic function, in the short-to medium-term.

The current most frequently used surgical intervention for the treatment of TGA is ASO. A significant body of data is available concerning complications that develop during the early postoperative period, whereas data concerning late complications during follow-up are limited. The greatest advantage of

ASO is that LV becomes the systemic ventricle because RV cannot function against the high-pressure systemic blood flow in the long-term because of its morphological features (1).

Factors such as strain and decreased diameter of the pulmonary arteries, compression of the proximal pulmonary branches due to their close anatomical relationship with the aorta, decreased elasticity caused by scar tissue at an anastomosis site, and hypoplasia in the pulmonary circulatory bed can increase the blood flow to the pulmonary artery, which subsequently increases the hemodynamic load of RV after ASO. Right ventricular hypertrophy, which is compensatory to the increase in right ventricular afterload, is associated with a decrease in pulmonary blood flow. Furthermore, the increase in right ventricular afterload and coronary circulation problems causes right ventricular hypertrophy, which in turn delays right ventricular relaxation (23).

Diastolic function is impaired before systolic function in a number of heart diseases. Therefore, knowledge of diastolic function has clinical significance. Diastolic dysfunction is also seen in ischemic diseases. In these patients, the early diastolic filling phase of the E-wave velocity decreases, late diastolic phase is unchanged or relatively increased, and E/A ratio is decreased. These symptoms usually occur before systolic dysfunction (24, 25). When the impaired right ventricular relaxation E/A ratio decreases (26). The peak E/A ratio is one of the better methods for assessing ventricular diastolic function (27). Grotenhuis et al. (23) used cardiac MRI to evaluate the right ventricle in 17 control and 17 ASO patients 16.5 years after surgery and observed a significantly lower tricuspid valve E/A peak flow velocity ratio as well as the presence of right ventricular hypertrophy and diastolic dysfunction in the absence of marked pulmonary stenosis in the patient group. They concluded that these findings are indicative of delayed right ventricular relaxation. The current results demonstrated that the RV E/A ratio was significantly lower in the patient group, which is consistent with the above-mentioned study.

Additional factors such as preload, afterload, and left ventricular performance make it difficult to assess right ventricular function using conventional methods (28). However, TDI allows regional myocardial velocities and systolic and diastolic intervals to be measured (29, 30). Therefore, TDI is superior and more sensitive than conventional echocardiography for detecting subclinical abnormalities in RV (28). Pulsed TDI of the tricuspid annulus is a noninvasive and reliable method for assessing RV function compared with the gold standard of MRI (31). Because diastolic dysfunction starts before systolic dysfunction, tissue Doppler echocardiography may be helpful in the early diagnosis of diastolic dysfunction (32, 33). Harada et al. (34) reported that an insufficient increase in Sa suggests an impaired response to exercise in RV of patients with tetralogy of Fallot. Amoozgar et al. (35) found that 33 children who underwent ASO had normal left ventricular function, although the lateral tricuspid tissue Doppler velocities were significantly lower in the patient group

compared with their control group. Therefore, the authors emphasized the necessity for long-term follow-up in patients who undergo ASO. The current results demonstrated that the tissue Doppler flow velocities in the mitral septal annulus and tricuspid lateral annulus were significantly lower in the patient group compared with the control group. These results suggest the presence of right ventricular diastolic dysfunction (36).

Tissue Doppler imaging can be used to evaluate global and regional ventricular performance in several clinical conditions. Van der Hulst et al. (37) found normal right and left ventricular tissue Doppler peak Sa in 123 healthy children. The data of the control group from our study and the data of the healthy children from this study were found to be similar; however, the TDI mitral septal annulus and tricuspid lateral annulus peak Sa were lower in the current patient group compared with normal subjects.

Klitsie et al. (38) evaluated the right and left ventricular systolic and diastolic performances of 26 patients who underwent ASO via TDI, tricuspid annular plane systolic excursion, mitral annular plane systolic excursion, and left ventricular strain rate preoperatively and then on postoperative day 1, at discharge, and 9 months after surgery. They reported that the left ventricular function recovered during follow-up but that the right ventricular damage remained; therefore, they emphasized the importance of evaluating right ventricular performance during postoperative follow-up.

Elevated filling pressures are the main physiological consequence of diastolic dysfunction (39). When assessing LV diastolic performance, tissue Doppler is more reliable than conventional Doppler because it is not affected by loading conditions and the TDI measurements are more reproducible (40). Diastolic abnormalities could be detected using TDI even before the onset of hemodynamic abnormalities was identified on conventional echocardiography (41). The E/Ea ratio is the best parameter to predict the mean LV filling pressures (42), and it is proportional to the severity of LV diastolic dysfunction. Although the LV E/Ea ratio was unchanged, the RV E/Ea ratio was higher in the patient group compared with the control group in the current study.

MPI is a non-geometric index of ventricular function that can be implemented easily to evaluate right and left ventricular function. Furthermore, blood pressure, heart rate, and ventricle geometry are not affected by MPI. Therefore, MPI may have great prognostic value in many different clinical situations (43). Following heart transplantation, one study reported 85% specificity and 82.5% sensitivity for acute cardiac rejection based on a criterion of $LV\ MPI \geq 0.47$ (44). The same study revealed 100% specificity and 90% sensitivity using an increase of $\geq 20.4\%$ from baseline. The authors emphasized that LV MPI is a sensitive and specific marker for acute cardiac rejection. Previous studies have reported a positive correlation between an increased LV MPI and dysfunctional capacity. The fact that the patient group had good functional capacity despite higher MPI supports the view that MPI is very important for monitoring patient prognosis because it facilitates the diagnosis of ventricular dysfunction

before clinical indications. In normal subjects, MPI has a narrow range, which increases progressively as LV function deteriorates. Other studies have reported a relationship between LV MPI and N-terminal-pro-B-type natriuretic peptide (45) and found that MPI was correlated significantly with the NYHA class, EF, and ventricular volumes. The current results revealed no difference in EF, FS, and LV mass index between the patient and control groups, whereas the left ventricular MPI was significantly higher in the patient group. It is possible that the impaired left ventricular MPI observed in the present study was associated with problematic microcirculation in the left coronary artery.

Study limitations

There are some limitations to the current study that should be considered. First, a longer follow-up period would have strengthened the results. Second, the number of patients was small because we do not have a pediatric cardiovascular surgery center. Third, the assessments of RV may be suboptimal because of its retrosternal localization and irregular crescent shape (28).

Conclusion

The findings of the present study suggest that the right ventricular conventional Doppler and tissue Doppler flows and the left ventricular MPI were impaired during the short-to mid-term follow-up of pediatric patients who underwent ASO. It is particularly important to evaluate right ventricular performance during long-term follow-up.

Conflict of interest: None declared.

Peer-review: Externally peer-reviewed.

Authorship contributions: Concept - T.Ö., V.T.; Design - T.Ö., B.G.; Supervision - V.T., M.M.Y.; Resource - V.T., T.M.; Materials - Ö.D., T.Ö.; Data collection &/or processing - T.Ö., R.Ö., Ö.D.; Analysis &/or interpretation - T.Ö., B.G.; Literature search - T.Ö.; Writing - T.Ö., R.Ö.; Critical review - T.Ö., R.Ö.; Other - R.Ö.

References

1. Mavroudis C, Backer CL (eds). Pediatric Cardiac Surgery, 3d ed. Philadelphia: Mosby; 2003; 442-75.
2. Jatene AD, Fontes VF, Paulista PP, Souza LC, Neger F, Galantier M, et al. Anatomic correction of transposition of the great vessels. J Thorac Cardiovasc Surg 1976; 72: 364-70.
3. Gewilig M, Cullen S, Mertens B, Lesaffre E, Deanfield J. Risk factors for arrhythmia and death after Mustard operation for simple transposition of the great arteries. Circulation 1991; 84(Suppl 3): 187-92.
4. Gelatt M, Hamilton RM, McCrindle BW, Connelly M, Davis A, Harris L, et al. Arrhythmia and mortality after the Mustard procedure: a 30-year single-center experience. J Am Coll Cardiol 1997; 29: 194-201. [\[CrossRef\]](#)

5. Khairy P, Clair M, Fernandes SM, Blume ED, Powell AJ, Newburger JW, et al. Cardiovascular outcomes after the arterial switch operation for D-transposition of the great arteries. *Circulation* 2013; 127: 331-9. [\[CrossRef\]](#)
6. Alam M, Witt N, Nordlander R, Samad BA. Detection of abnormal left ventricular function by Doppler tissue imaging in patients with a first myocardial infarction and showing normal function assessed by conventional echocardiography. *Eur J Echocardiogr* 2007; 1: 37-41. [\[CrossRef\]](#)
7. Dagianti A, Vitarelli A, Conde Y, Penco M, Fedele F, Dagianti A. Assessment of regional left ventricular function during exercise test with pulsed tissue Doppler imaging. *Am J Cardiol* 2000; 4A: 30G-2G. [\[CrossRef\]](#)
8. Meluzin J, Spinarova L, Bakala J, Toman J, Krejci J, Hude P, et al. Pulsed Doppler tissue imaging of the velocity of tricuspid annular systolic motion; a new, rapid, and non-invasive method of evaluating right ventricular systolic function. *Eur Heart J* 2001; 4: 340-8. [\[CrossRef\]](#)
9. Mogelvang R, Sogaard P, Pedersen SA, Olsen NT, Marott JL, Schnohr P, et al. Cardiac dysfunction assessed by echocardiographic tissue Doppler imaging is an independent predictor of mortality in the general population. *Circulation* 2009; 20: 2679-85. [\[CrossRef\]](#)
10. Uebing A, Gibson DG, Babu-Narayan SV, Diller GP, Dimopoulos K, Göktekin O, et al. Right ventricular mechanics and QRS duration in patients with repaired tetralogy of Fallot: implications of infundibular disease. *Circulation* 2007; 14: 1532-9. [\[CrossRef\]](#)
11. Ypenburg C, Westenberg JJ, Bleeker GB, Van D, Marsan NA, Henneman MM, et al. Noninvasive imaging in cardiac resynchronization therapy-Part 1: selection of patients. *Pacing Clin Electrophysiol* 2008; 11: 1475-99. [\[CrossRef\]](#)
12. Frea S, Capriolo M, Bergamasco L, Iacovino C, Quaglia FC, Ribezzo M, et al. Prognostic role of myocardial performance index on long-term survival after heart transplantation: a prospective study. *Echocardiography* 2013; 30: 1033-41. [\[CrossRef\]](#)
13. Lopez L, Colan SD, Frommelt PC, Ensing GJ, Kendall K, Younoszai AK, et al. Recommendations for quantification methods during the performance of a pediatric echocardiogram: a report from the Pediatric Measurements Writing Group of the American Society of Echocardiography Pediatric and Congenital Heart Disease Council. *J Am Soc Echocardiogr* 2010; 23: 465-95. [\[CrossRef\]](#)
14. Koldaş L, Ayan F, İlerigelen B, Sirmacı N. Assessment of left ventricular ejection fraction by acoustic quantification: comparison with conventional 2-dimensional echocardiography. *Arch Turk Soc Cardiol* 1996; 24: 160-3.
15. Weil BR, Herrmann JL, Abarbanell AM, Manukyan MC, Poynter JA, Meldrum DR. Intravenous infusion of mesenchymal stem cells is associated with improved myocardial function during endotoxemia. *Shock* 2011; 36: 235-41. [\[CrossRef\]](#)
16. Yu CM, Sanderson JE, Marwick TH, Oh JK. Tissue Doppler imaging a new prognosticator for cardiovascular diseases. *J Am Coll Cardiol* 2007; 49: 1903-14. [\[CrossRef\]](#)
17. Harada K, Tamura M, Yasuoka K, Toyono M. A comparison of tissue Doppler imaging and velocities of transmitral flow in children with elevated left ventricular preload. *Cardiol Young* 2001; 11: 261-8. [\[CrossRef\]](#)
18. Tei C, Ling LH, Hodge DO, Bailey KR, Oh JK, Rodeheffer RJ, et al. New index of combined systolic and diastolic myocardial performance: a simple and reproducible measure of cardiac function a study in normal and dilated cardiomyopathy. *J Cardiol* 1995; 26: 357-66.
19. Hourihan M, Colan SD, Wernovsky G, Maheswari U, Mayer JE Jr, Sanders SP. Growth of the aortic anastomosis, annulus, and root after the arterial switch procedure performed in infancy. *Circulation* 1993; 88: 615-20. [\[CrossRef\]](#)
20. Weindling SN, Wernovsky G, Colan SD, Parker JA, Boutin C, Mone SM, et al. Myocardial perfusion, function and tolerance after the arterial switch operation. *J Am Coll Cardiol* 1994; 23: 424-33. [\[CrossRef\]](#)
21. Moe GW, Angus C, Howard RJ, De Bold AJ, Armstrong PW. Pathophysiological role of changing atrial size and pressure in modulation of atrial natriuretic factor during evolving experimental heart failure. *Cardiovasc Res* 1990; 24: 570-7. [\[CrossRef\]](#)
22. Devereux RB, Alonso DR, Lutas EM, Gottlieb GJ, Campo E, Sachs I, et al. Echocardiographic assessment of left ventricular hypertrophy: comparison to necropsy findings. *Am J Cardiol* 1986; 57: 450-8. [\[CrossRef\]](#)
23. Grotenhuis HB, Kroft LJ, van Elderen SG, Westenberg JJ, Doornbos J, Hazekamp MG, et al. Right ventricular hypertrophy and diastolic dysfunction in arterial switch patients without pulmonary artery stenosis. *Heart* 2007; 93: 1604-8. [\[CrossRef\]](#)
24. Lorell BH. Significance of diastolic dysfunction of the heart. *Annu Rev Med* 1991; 42: 411-36. [\[CrossRef\]](#)
25. Miki S, Murakami T, Iwase T, Tomita T, Suzuki Y, Kawai C. Dependence of Doppler echocardiographic transmitral early peak velocity on left ventricular systolic function in coronary artery disease. *Am J Cardiol* 1991; 67: 470-8. [\[CrossRef\]](#)
26. Lorell BH, Grossman W. Cardiac hypertrophy: the consequences for diastole. *J Am Coll Cardiol* 1987; 9: 1189-93. [\[CrossRef\]](#)
27. Diwan A, McCulloch M, Lawrie GM, Reardon MJ, Nagueh SF. Doppler estimation of left ventricular filling pressures in patients with mitral valve disease. *Circulation* 2005; 111: 3281-9. [\[CrossRef\]](#)
28. Chow PC, Liang XC, Cheung EW, Lam WW, Cheung YF. New two-dimensional global longitudinal strain and strain rate imaging for assessment of systemic right ventricular function. *Heart* 2008; 94: 855-9. [\[CrossRef\]](#)
29. Matsui H, Satomi G, Yasukochi S, Kaneko S, Haseyama K. Evaluation of right ventricular contraction by myocardial strain in children using a two-dimensional tissue tracking method. *Pediatr Cardiol* 2008; 29: 377-81. [\[CrossRef\]](#)
30. Moiduddin N, Texter KM, Zaidi AN, Hershenson JA, Stefaniak CA, Hayes J, et al. Two-dimensional speckle strain and dyssynchrony in single right ventricles. *Congenit Heart Dis* 2010; 5: 579-86. [\[CrossRef\]](#)
31. Harada K, Tamura M, Toyono M, Yasuoka K. Comparison of right ventricular Tei index by tissue Doppler imaging to that obtained by pulsed Doppler in children without heart disease. *Am J Cardiol* 2002; 90: 566-9. [\[CrossRef\]](#)
32. Cullen S, Shore D, Redington A. Characterization of right ventricular diastolic performance after complete repair of tetralogy of Fallot. Restrictive physiology predicts slow postoperative recovery. *Circulation* 1995; 91: 1782-9. [\[CrossRef\]](#)
33. Gatzoulis MA, Clark AL, Cullen S, Newman CG, Redington AN. Right ventricular diastolic function 15 to 35 years after repair of tetralogy of Fallot. *Circulation* 1995; 91: 1775-81. [\[CrossRef\]](#)
34. Harada K, Toyono M, Yamamoto F. Assessment of right ventricular function during exercise with quantitative Doppler tissue imaging in children late after repair of tetralogy of Fallot. *J Am Soc Echocardiogr* 2004; 17: 863-9. [\[CrossRef\]](#)
35. Amoozgar H, Salamina S, Amirghofran AA, Cheriki S, Borzoe M, Ajami G, et al. Evaluation of cardiac and valvular function after arterial switch operation: a midterm follow-up. *Int Cardiovasc Res J* 2013; 7: 83-9.
36. Bruch C, Stypmann J, Grude M, Gradaus R, Breithardt G, Wichter T. Tissue Doppler Imaging in patients with moderate to severe aortic

- valve stenosis: clinical usefulness and diagnostic accuracy. *Am Heart J* 2004; 148: 696-702. [\[CrossRef\]](#)
37. Van der Hulst AE, Delgado V, Ten Harkel AD, Klitsie LM, Filippini LH, Bax JJ, et al. Tissue Doppler imaging in the left ventricle and right ventricle in healthy children: normal age-related peak systolic velocities, timings, and time differences. *Eur J Echocardiogr* 2011; 12: 953-60. [\[CrossRef\]](#)
38. Klitsie LM, Roest AA, Kuipers IM, Hazekamp MG, Blom NA, Ten Harkel AD. Left and right ventricular performance after arterial switch operation. *J Thorac Cardiovasc Surg* 2014; 147: 1561-7. [\[CrossRef\]](#)
39. Brutsaert DL, Sys SU, Gillebert TC. Diastolic failure: pathophysiology and therapeutic implications. *J Am Coll Cardiol* 1993; 22: 318-25. [\[CrossRef\]](#)
40. Galderisi M, Nistri S, Ansalone G, Dini FL, Di Salvo G, Gallina S, et al. Pulsed tissue Doppler illustrated to a resident in cardiology. *G Ital Cardiol* 2007; 8: 92-101.
41. Aurigemma GP, Gottdiener JS, Shemanski L, Gardin J, Kitzman D. Predictive value of systolic and diastolic function for incident congestive heart failure in the elderly: the Cardiovascular Health Study. *J Am Coll Cardiol* 2001; 37: 1042-8. [\[CrossRef\]](#)
42. Ommen SR, Nishimura RA, Appleton CP, Miller FA, Oh JK, Redfield MM, et al. Clinical utility of Doppler echocardiography and tissue Doppler imaging in the estimation of left ventricular filling pressures: a comparative simultaneous Doppler-catheterization study. *Circulation* 2000; 102: 1788-94. [\[CrossRef\]](#)
43. Jurko A Jr, Jurko A, Minarik M. Doppler-derived myocardial performance index in healthy children. *Bratisl Lek Listy* 2011; 112: 77-9.
44. Flanagan R, Cain N, Tatum GH, Debrunner MG, Drant S, Feingold B. Left ventricular myocardial performance index change for detection of acute cellular rejection in pediatric heart transplantation. *Pediatr Transplant* 2013; 17: 782-6. [\[CrossRef\]](#)
45. Mikkelsen KV, Moller JE, Bie P, Ryde H, Videbaek L, Haghfelt T. Tei index and neurohormonal activation in patients with incident heart failure: serial changes and prognostic value. *Eur J Heart Fail* 2006; 8: 599-608. [\[CrossRef\]](#)