

“Frog Sign” in paroxysmal supraventricular tachycardia 🎥

A 70-year-old man without any previous medical history presented to the emergency department with complaint of palpitation for 2 h. On admission, his arterial blood pressure was 145/95 mmHg. Examination of the neck revealed rapid and regular pulsations with bulging of the internal jugular veins (Video 1). A 12-lead electrocardiogram was obtained and it revealed regular, narrow-complex tachycardia with a ventricular rate of 149 bpm (Figure 1a). On application of pressure to the carotid sinus, tachycardia and bulging of the internal jugular veins were not resolved. Tachycardia and pulsations in the neck were terminated, and sinus rhythm was restored with 5 mg of intravenous metoprolol (Figure 1b). An electrophysiological study was performed and confirmed the diagnosis of atrioventricular nodal reentrant tachycardia (AVNRT). The patient underwent radiofrequency ablation in the region of the slow pathway, and the arrhythmia was resolved.

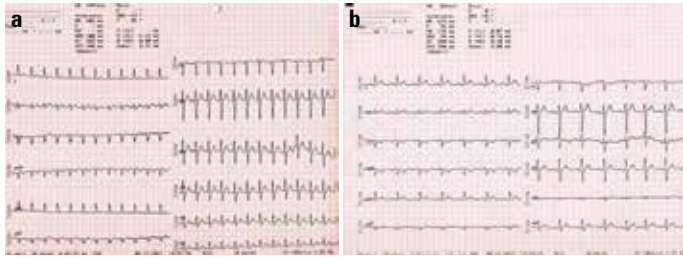


Figure 1. (a) Admission ECG showing regular, narrow-complex tachycardia with a ventricular rate of 149 bpm; (b) ECG obtained after termination of tachycardia with intravenous metoprolol

In AVNRT, anterograde conduction occurs over the slow pathway to the ventricle, whereas near-simultaneous atrial activation occurs over the fast pathway of the AV node. These events lead to the parallel electrical activation of the atria and ventricles. Canon A waves which occur with AV dissociation result from simultaneous contractions of the atria and ventricles against closed mitral and tricuspid valves, causing reflux of blood into the neck veins. The characteristic flapping or bulging appearance of the neck veins is also described as the “Frog sign.” “Frog sign” during narrow QRS complex tachycardia has been considered to be particularly helpful in making the diagnosis of typical AVNRT. An atrioventricular mechanical dissociation may also occur in the case of ventricular extrasystoles. In this case, however, only one or few pulses are felt in the neck, and the rhythm is more irregular. Knowledge of these classic signs is often helpful in determining the underlying condition.

Video 1. Rapid and regular jugular venous pulsations produced because of regular canon “a” waves is shown.

Yalçın Velibey, Furkan Durak, Ceyhan Türkan, Ahmet Taha Alper
Department of Cardiology, Siyami Ersek Thoracic and
Cardiovascular Surgery Center, Training and Research Hospital;
Istanbul-Turkey

Address for Correspondence: Dr. Yalçın Velibey,
 Dr. Siyami Ersek Hastanesi, Tıbbiye Sok. No: 25,
 Üsküdar, İstanbul-Türkiye
 Phone: +90 216 444 52 57
 Fax: +90 216 337 97 19
 E-mail: dr_yalchin_dr@yahoo.com.tr

©Copyright 2018 by Turkish Society of Cardiology - Available online
 at www.anatoljcardiol.com
 DOI:10.14744/AnatolJCardiol.2018.78045