

Electroanatomic mapping-guided pediatric catheter ablation with limited/zero fluoroscopy

 Serhat Koca,  Feyza Ayşenur Paç,  Deniz Eriş,  Merve Maze Zabun,  Özcan Özeke*,  Fırat Özcan*

Departments of Pediatric Cardiology, *Cardiology, Division of Arrhythmia and Electrophysiology, Yüksek İhtisas Training and Research Hospital; Ankara-Turkey

ABSTRACT

Objective: The use of fluoroscopy in pediatric catheter ablation has decreased because of mapping systems. In this study, we present the efficiency and reliability of the electroanatomic mapping system in nonfluoroscopic pediatric catheter ablation.

Methods: The medical records of patients aged <18 years who underwent ablation between November 2016 and April 2018 were evaluated. Fluoroscopy was not used in cases involving ablation of right sided-arrhythmia foci. Fluoroscopy was used only for trans-septal puncture or retroaortic approach/coronary angiography.

Results: A total of 76 patients underwent catheter ablation for 78 supraventricular and ventricular tachyarrhythmia substrates under the guidance of EnSite Velocity system. Fluoroscopy was used in only 14 (18.4%) of these substrates. The mean fluoroscopy duration in these 14 procedures was 5.4±3.15 min. No complications were noted, except a temporary right bundle branch block in one patient and pericardial effusion in another following cryoablation. The acute success rate in achieving complete elimination of arrhythmia substrates was 97.4% (76/78). The recurrence rate was 5.1% (4/78) at follow-up.

Conclusion: Fluoroscopy can be completely eliminated in most pediatric catheter ablation procedures with the use of mapping systems by achieving high acute success rates and acceptable low complication rates. (*Anatol J Cardiol* 2018; 20: 159-64)

Keywords: electroanatomic mapping system, pediatric catheter ablation, tachycardia, cryoablation

Introduction

Currently, catheter ablation has become a curative method that should be considered as the first choice for treating children with tachyarrhythmia, because it has few complications and high success rates (1, 2). Electrophysiological study (EPS) and catheter ablation are generally performed under fluoroscopy. The mean fluoroscopy duration is approximately 18–38 min, and this duration exceeds 50 min in 20% of pediatric cases (3, 4). The carcinogenic impact of radiation used during catheterization in pediatric patients with long life expectancies who are sensitive to radiation must be considered (5-7). The dose of radiation used during catheter ablation in pediatric patients can be reduced using three-dimensional electroanatomic mapping systems (3D EAMs). The objective of this study was to evaluate the results of catheter ablation performed with limited/zero fluoroscopy in pediatric patients in a pediatric cardiology center.

Methods

Study population

A total of 76 patients [male/female (M/F)=41/35] aged <18 years who were referred for catheter ablation and underwent ablation procedure between November 2016 and February 2018 were included in this study. Data regarding clinical characteristics, electrocardiographic and Holter findings, echocardiographic examinations, ablation procedures, and follow-up were obtained from hospital records. This study was approved by the Local Ethical Committee of our hospital.

Electrophysiological study and ablation therapy

A tetrapolar 5F catheter was inserted into the right atrium without using fluoroscopy via the right femoral vein as the standard procedure in all patients. Tachycardia inducibility was evaluated with incremental and programmed atrial pacing

The summary of preliminary results of this study presented as oral presentation in 14th International Congress of Update in Cardiology and Cardiovascular Surgery Congress in Antalya 5-8 April 2018.

Address for correspondence: Dr. Serhat Koca, Ankara Türkiye Yüksek İhtisas Eğitim ve Araştırma Hastanesi, Çocuk Kardiyoloji Kliniği, Ankara-Türkiye

Phone: +90 506 581 8248 Fax: +90 312 312 4120 E-mail: drserhatkoca@gmail.com

Accepted Date: 08.06.2018 **Available Online Date:** 06.08.2018

©Copyright 2018 by Turkish Society of Cardiology - Available online at www.anatoljcardiol.com
DOI:10.14744/AnatolJCardiol.2018.72687



where good atrial signals were received. In patients with Wolff Parkinson White pattern (WPW); the conduction properties of accessory pathway (AP), were assessed. The antegrade conduction of the manifest AP measured during EPS was classified as risky conduction if any of the following three conditions were met: 1:1 conduction through AP to a paced cycle length of ≤ 250 ms using incremental or burst atrial pacing; an AP-effective refractory period of ≤ 250 ms on a single atrial extrastimulus protocol; or shortest pre-excited RR interval during atrial fibrillation of ≤ 250 ms (8). Ablation procedures were performed in patients scheduled for ventricular premature beat (VPB) ablation on outpatient evaluation, those with high-risk WPW patients, and those with inducible tachycardia. At this instance, two sheaths were inserted in the left femoral vein in patients planned to undergo ablation, and a three-dimensional electroanatomic mapping system (3D EAM; EnSite Velocity system, St. Jude Medical, St. Paul, MN) was activated. After 3D EAM activation, the right atrial anatomy was created using the inserted catheter in the right atrium via the right femoral vein. After creating the right atrial anatomy, the Bundle of His and the entrances of the caval veins to the right atrium were marked. Catheters were placed into the right atrium, coronary sinus, and right ventricle under the guidance of the EnSite Velocity system without fluoroscopy. There were no cases with failed catheter insertion to the coronary sinus. Femoral artery puncture was performed only for patients with left-ventricular-originating arrhythmia substrates to carry out a retroaortic approach. Ventricular and atrial stimulation protocols were used to assess conduction properties and to determine the tachycardia mechanism. No fluoroscopy was used in the ablation of the right atrial and ventricular arrhythmia foci. When a left-sided arrhythmogenic substrate was detected in the patient, we first investigated whether there was patent foramen ovale (PFO) in the posterosuperior of the His point at the septal site; if yes, the left atrium was accessed via the foramen ovale, and ablation was performed. Fluoroscopy was used for trans-septal puncture in patients requiring access to the left atrium and for retroaortic approach/coronary angiography in the ablation of left-ventricular-originating arrhythmias. In atrioventricular reentrant tachycardia (AVNRT) and right anterolateral, anteroseptal, and midseptal AP ablations, only cryoablation was used. The cryocatheters were selected according to the patient's weight, arrhythmia substrate, and preference of the operator as a 7F 6-mm or 9F 8-mm tip (Medtronic, Minneapolis, USA). Radio-frequency (RF) ablation catheters were selected according to the arrhythmia substrate and preference of the operator as 7F 4-mm tip ablation catheters (Mariner RF, Medtronic) or 7F irrigated RF ablation catheters (FlexAbility, St. Jude Medical). All ablations were performed by the same pediatric electrophysiologist. After successful ablation, there was a 30-min waiting period to assess recurrence. After the waiting period, the success of the manifest AP ablation was evaluated with adenosine only in patients with manifest pre-excitation. Postprocedural tachycardia inducibility was controlled with atrial/ventricular pacing in association with intravenous metoprolenol sulfate administration.

Follow-up

Continuous telemetry monitoring, 12-lead electrocardiography (ECG), Holter monitoring, and echocardiography were performed on the day of the procedure in all patients who underwent ablation. The patients were discharged 24 h after the procedure. They were questioned for symptoms at the 1- and 6-month follow-ups and evaluated with ECG, echocardiography, and Holter monitoring at each visit.

Statistical analysis

Analyses were performed using SPSS 15 software (SPSS, Inc., Chicago, IL, USA). The distribution pattern of the data was evaluated using the Kolmogorov–Smirnov test. Continuous data were presented as the mean \pm SD or median (interquartile range), whichever appropriate. Categorical variables were summarized as percentages.

Results

Baseline characteristics

A total of 78 arrhythmia substrates were ablated in 76 patients (M/F=41/35). The concomitant cardiac defect was ASD/

Table 1. Clinical characteristics of patients undergoing catheter ablation

Characteristic	Total, n=76
Age at ablation, years (median, 25 th and 75 th IQR, years)	13 (11-16)
Sex (M/F)	41/35
Weight, kg (average \pm SD)	51.22 \pm 14.56
Initial ECG findings, n (%)	
- Normal	2 (2.6%)
- Manifest pre-excitation (WPW)	28 (36.8%)
- VPB	3 (3.9%)
- Narrow QRS tachycardia	42 (55.2%)
o Short RP interval	40 (52.6%)
o Long RP interval	2 (2.6%)
- Wide QRS tachycardia	1 (1.3%)
Symptoms (n, %)	
- Asymptomatic	13 (17.1%)
- Presyncope/syncope	2 (2.6%)
- Palpitation	61 (80.2%)
Associated cardiac defects	
- ASD/PFO	6 (7.9%)

Values are given as count (%), median with interquartile range, or mean \pm SD, as appropriate.

ECG - electrocardiography; F - female; M - male; VPB - ventricular premature beat; ASD - atrial septal defect; PFO - patent foramen ovale; WPW - Wolff-Parkinson-White; SD - standard deviation; IQR - interquartile range

PFO in only six patients. According to baseline ECG of the patients who underwent ablation, documented tachycardia was found in 43 (56.5%) patients and manifest pre-excitation in 28 (36.8%). There was no pre-excitation on the sinus rhythm ECG of patients with documented tachycardia. Only 13 (17.1%) patients were asymptomatic, all of whom had WPW patterns. The WPW pattern was also found in two patients who reported pre-syncope/syncope. The clinical characteristics of the patients who underwent catheter ablation are shown in Table 1.

Electrophysiological characteristics and ablation results

Electrophysiological properties and ablation results are shown in Table 2. The majority of the ablation substrates were typical AVNRT (43.5%). Successful VPB ablations (100%) were performed in four patients, with two localized in the right ventricular outflow tract and remaining two in the left ventricular outflow tract (LVOT). Successful RF ablations (100%) were performed in three patients with focal atrial tachycardia (FAT), with one localized in the right-upper pulmonary vein, one in the septum, and one in the crista terminalis. Typical AVNRT was induced following successful RF ablation in one patient with WPW pattern and other with concealed AP. Successful typical AVNRT cryoablations were carried out after AP ablation in two patients. Ablation procedures were successful in all the patients with AVNRT and concealed AP. AP conduction could

not be eliminated in only two asymptomatic patients with WPW patterns.

Successful ablations were performed in the left atrium with trans-septal puncture in one patient with FAT, five with left-sided concealed AP, and five with left-sided manifest AP, whereas successful radiofrequency ablation was performed via PFO in three patients with left-sided manifest AP.

When ablation with a 7F 4-mm tip RF ablation catheter failed in three right posteroseptal localized AP cases (two manifest AP and one concealed AP), successful ablation was achieved using an 8-mm tip cryocatheter. Among the four successful VPB ablations, three were performed with irrigated RF ablation catheters and one with a 7F 4-mm tip RF ablation catheter. Two anterolateral AP and 14 AVNRT ablations were successfully performed with 9F 8-mm tip cryocatheters. Two anterolateral APs, two antero-septal APs, four midseptal APs, and 20 AVNRT ablations were successfully performed with 7F 6-mm cryocatheters. One VPB, three FATs, 13 left-sided APs, seven right posteroseptal APs, one right posterior AP, one anterolateral AP, and one fascicular ventricular tachycardia ablation were successfully performed with a 7 F 4-mm tip RF ablation catheter.

The mean total procedure duration was 153.1±44.3 min. No anesthesia-related complications were seen in any patient. The patients who underwent trans-septal puncture did not develop complications. Spontaneously resolved pericardial effusion was

Table 2. Electrophysiological characteristics and ablation results of patients

Ablation substrats, n	78	AP substrate location, manifest/concealed, n	28/8
Manifest AP (WPW)	28	Anteroseptal	2/0
Concealed AP	8	Midseptal	3/1
Focal atrial tachycardia	3	Right posterior	1/0
Typical AVNRT	32	Right posteroseptal	10/1
Atypical AVNRT	2	Right anterolateral	4/1
VPB	4	Left lateral	6/3
Fascicular VT	1	Left posterior	2/2
Acute success [n/total (%)]		Recurrence at follow-up of 43.4±23.3 weeks [n (%)]	4 (5.2)*
- By patient	74/76 (97.3)		
- By tachycardia substrates	76/78 (97.4)	Fluoroscopy time, minutes, mean±SD	5.4±3.15**
Manifest AP (WPW)	26/28 (92.8)		
Concealed AP	8/8 (100)	Total procedure duration, min, mean±SD	153.1±44.3
Focal atrial tachycardia	3/3 (100)		
Typical AVNRT	32/32 (100)		
Atypical AVNRT	2/2 (100)	Complication (n)	2***
VPB	4/4 (100)		
Fascicular VT	1/1 (100)		

*1 WPW, 1 concealed AP, and 2 AVNRT recurred after 2, 1, 5, and 6 months after the procedure, respectively.

**14 patients who required fluoroscopy have been included in these averages.

***1 transient right bundle branch block and 1 pericardial effusion, which resolved spontaneously

AP - accessory pathway; AVNRT - atrioventricular nodal reentrant tachycardia; VT - ventricular tachycardia; WPW - Wolff-Parkinson-White syndrome

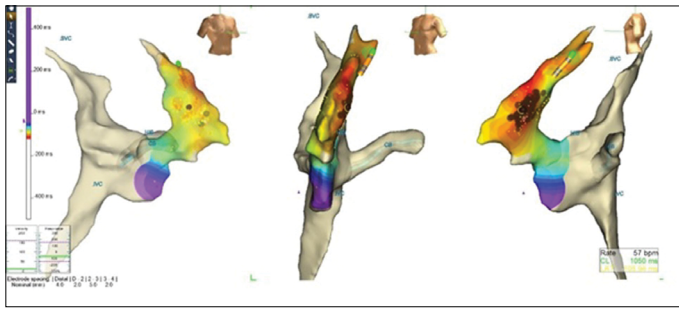


Figure 1. This figure shows radiofrequency (RF) ablation of ventricular premature beats (VPB) in a 16-year-old girl. The red dots indicate midseptal localizations, which were successfully VPB-ablated in the right oblique, left oblique, and lateral positions with EnSite Velocity system. Successful ablation was performed with a 7F 4-mm tip RF ablation catheter. The duration of the procedure was 120 min and of fluoroscopy was 0 min

observed in one and a transient right bundle block in one of the two patients who underwent AVNRT ablation with an 8-mm tip cryoablation catheter (Table 2).

Fluoroscopy usage

3D EAM was used in all patients. Fluoroscopy with 3D EAM was used in only 14 patients. The ablation procedure was applied without fluoroscopy and with a cryocatheter in all patients with AVNRT. No fluoroscopy was used in patients with right atrial and right ventricular arrhythmia substrates (Fig. 1). The mean fluoroscopy duration was 5.4 ± 3.15 min in 14 patients. The association between coronary arteries and foci to be ablated was evaluated in patients who underwent LVOT-originated VPB ablation.

Follow-up

The follow-up duration for patients was 43.4 ± 23.3 weeks. One WPW, one concealed AP, and two AVNRT recurred after 2, 1, 5, and 6 months, respectively. The VPB load was $<1\%$ on Holter monitoring of patients who underwent successful VPB ablation. In the patients with recurrence, ablation was successful in their second session.

Discussion

In this study, we presented the results of 3D mapping system-guided catheter ablation performed using zero/limited fluoroscopy in pediatric and adolescent patients in a center. The most important conclusions of this study are as follows:

1. Right-sided arrhythmia substrates that are common in children and adolescents with normal cardiac anatomy can be completely ablated without fluoroscopy.
2. Acute success and short-term follow-up outcomes were excellent in completely fluoroscopy-free AVNRT cryoablation.

An important point to note regarding catheter ablation in pediatric patients is the prolonged fluoroscopy duration which

may be required. The mean fluoroscopy duration has been reported to be 28.5–38.3 min and >50 min in 20% of pediatric catheter ablation cases (3). This is crucial for both the patients and laboratory staff (9-11). Although the duration is not expected to be long, fluoroscopy times between 16 and 27 minutes have been reported in AVNRT ablations in the literature (3,4). The limitation of fluoroscopy in supraventricular tachycardia ablation, which is frequently performed in pediatric electrophysiology clinics, is quite satisfying. Recently, zero fluoroscopy has been aimed in pediatric AVNRT ablation, and a few studies have been conducted on this issue (12-16). However, although these studies have reported significant reduction in the use of fluoroscopy in AVNRT ablation, it could not be completely eliminated.

Visualization of catheters and cardiac anatomy from different angles after obtaining 3D anatomy of the cardiac chambers via 3D EAM largely eliminates the need for fluoroscopy. According to the literature, with increasing experience, further reduction has been achieved in the operational and fluoroscopy durations using 3D EAM. In our study, the total procedure duration of 153.1 ± 44.3 min and mean fluoroscopy duration of 5.4 ± 3.15 min in cases with fluoroscopy are consistent with the literature (13-17).

Published reports have shown that cryoablation can be safely and effectively used, particularly for treatment of AVNRT and supraventricular tachyarrhythmia with AP (18, 19). In our study, cryoablation was used effectively, and no major complications were seen. A study demonstrated that a cryoablation system can produce larger lesions than open-irrigated RF ablation (20). In our study, cryoablation with 8-mm tip cryocatheter was successful in three patients in whom RFA had previously failed.

Trans-septal puncture has been used for 20 years for the ablation of left-sided arrhythmia foci with an acceptable rate of complications in pediatric electrophysiology (21, 22). No trans-septal puncture-related complication was seen in our study. In routine electrophysiological studies performed in pediatric patients in our hospital, the presence of PFO was investigated before the trans-septal puncture when a left-sided arrhythmogenic substrate was detected. Ablation was performed without fluoroscopy in three left-sided arrhythmogenic substrates. We believe that the need for trans-septal puncture decreases when ablation of the left atrial localized arrhythmia foci is performed via PFO. Thus, the use of fluoroscopy could also be limited. Similarly, another approach to increase the proportion of children who undergo zero fluoroscopy ablation is the use of a cryoablation catheter in right lateral annulus localized AP ablations. The stability of the radiofrequency ablation catheter is low in the right atrium anterolateral-anterior region. However, the catheter's stability should be enhanced for successful ablation and fewer complications. For this purpose, if ablation is performed using radiofrequency catheters, it is necessary to insert a long sheath under the guidance of fluoroscopy. In the

present study, successful ablations were performed with zero fluoroscopy in four children who underwent right anterolateral localized AP ablation using a cryocatheter.

A 7F 4-mm tip RF catheter and irrigated RF catheter were used in two patients with right posteroseptal localized manifest AP, in whom the operation failed. AP was thought to be epicardially localized in these patients, who were complaint-free and had a low risk, as detected on EPS. These patients are being followed without medication.

A shift may occur in the created geometry because of patient movement during the 3D EAM procedure (16). This may produce important errors on the 3D map. Therefore, we inserted the ablation catheter in pediatric patients under deep sedation or general anesthesia. Locations of catheters in the heart would be better visualized if the anatomy of the cardiac chamber could be detailed using 3D EAM systems. Therefore, fluoroscopy should be available to determine the catheter location if there is suspected localization of the catheter within the cardiac chambers.

The number of pediatric patients who would undergo complete fluoroscopy-free successful ablation will increase with the experience of operators and advancements in 3D EAM and ablation technologies.

Study limitation

Limited number of patients and relatively short follow-up duration were the study limitations. Fluoroscopy in trans-septal puncture can be reduced using intracardiac or transesophageal echocardiography. No echocardiography was used during trans-septal puncture in our patients.

Conclusion

In this study, we demonstrated that catheter ablation can be performed with limited/zero usage of fluoroscopy, low rates of complication, and excellent rates of acute success using 3D EAM systems in arrhythmia substrates in pediatric patients with normal cardiac anatomy. Left atrial arrhythmia substrate ablation performed via PFO in patients requiring trans-septal puncture will reduce the number of cases needing fluoroscopy. Similarly, performing ablations of right lateral-anterolateral localized arrhythmia substrates using a cryocatheter can reduce the number of cases requiring fluoroscopy. Further controlled studies with a larger number of patients are needed.

Conflict of interest: None declared.

Peer-review: Externally peer-reviewed.

Authorship contributions: Concept – S.K., F.A.P.; Design – S.K., D.E.; Supervision – Ö.Ö., F.Ö.; Fundings – None; Materials – None; Data collection &/or processing – S.K., M.M.Z.; Analysis &/or interpretation – F.A.P., D.E., M.M.Z.; Literature search – S.K.; Writing – S.K.; Critical review – Ö.Ö., F.Ö.

References

1. Pietrzak R, Lodzinski P, Ksiaczczyk T, Balsam P, Gawatko M, Opolski G, et al. Initial experience of catheter ablation for cardiac arrhythmias in children and adolescents at a newly built ablation centre. *Kardiol Pol* 2018; 76: 130-5. [\[CrossRef\]](#)
2. Swissa M, Birk E, Dagan T, Naimer SA, Fogelman M, Einbinder T, et al. Radiofrequency catheter ablation of atrioventricular node reentrant tachycardia in children with limited fluoroscopy. *Int J Cardiol* 2017; 236: 198-202. [\[CrossRef\]](#)
3. Van Hare GF, Javitz H, Carmelli D, Saul JP, Tanel RE, Fischbach PS, et al. Prospective assessment after pediatric cardiac ablation: demographics, medical profiles, and initial outcomes. *J Cardiovasc Electrophysiol* 2004; 15: 759-70. [\[CrossRef\]](#)
4. Kubus P, Vít P, Gebauer RA, Zaoral L, Peichl P, Fiala M, et al. Long-term results of paediatric radiofrequency catheter ablation: a population-based study. *Europace* 2014; 16: 1808-13. [\[CrossRef\]](#)
5. Justino H. The ALARA concept in pediatric cardiac catheterization: Techniques and tactics for managing radiation dose. *Pediatr Radiol* 2006; 36 Suppl 2: 146-53. [\[CrossRef\]](#)
6. Kleinerman RA. Cancer risks following diagnostic and therapeutic radiation exposure in children. *Pediatr Radiol* 2006; 36 Suppl 2: 121-5. [\[CrossRef\]](#)
7. Wagner LK. Minimizing radiation injury and neoplastic effects during pediatric fluoroscopy: What should we know? *Pediatr Radiol* 2006; 36 Suppl 2: 141-5. [\[CrossRef\]](#)
8. Koca S, Pac FA, Kavurt AV, Cay S, Mihcioglu A, Aras D, et al. Transesophageal and invasive electrophysiologic evaluation in children with Wolff-Parkinson-White pattern. *Pacing Clin Electrophysiol* 2017; 40: 808-14. [\[CrossRef\]](#)
9. Bashore TM, Bates ER, Berger PB, Clark DA, Cusma JT, Dehmer GJ, et al.; American College of Cardiology. Task Force on Clinical Expert Consensus Documents. American College of Cardiology/Society for Cardiac Angiography and Interventions Clinical Expert Consensus Document on cardiac catheterization laboratory standards. A report of the American College of Cardiology Task Force on Clinical Expert Consensus Documents. *J Am Coll Cardiol* 2011; 37: 2170-214.
10. Venneri L, Rossi F, Botto N, Andreassi MG, Salcone N, Emad A, et al. Cancer risk from professional exposure in staff working in cardiac catheterization laboratory: Insights from the National Research Council's Biological Effects of Ionizing Radiation VII Report. *Am Heart J* 2009; 157: 118-24. [\[CrossRef\]](#)
11. Efstathopoulos EP, Katritsis DG, Kottou S, Kalivas N, Tzanalaridou E, Giazitzoglou E, et al. Patient and staff radiation dosimetry during cardiac electrophysiology studies and catheter ablation procedures: A comprehensive analysis. *Europace* 2006; 8: 443-8.
12. Wan G, Shannon KM, Moore JP. Factors associated with fluoroscopy exposure during pediatric catheter ablation utilizing electro-anatomical mapping. *J Interv Card Electrophysiol* 2012; 35: 235-42.
13. Smith G, Clark JM. Elimination of fluoroscopy use in a pediatric electrophysiology laboratory utilizing three-dimensional mapping. *Pacing Clin Electrophysiol* 2007; 30: 510-8. [\[CrossRef\]](#)
14. Papagiannis J, Avramidis D, Alexopoulos C, Kirvassilis G. Radiofrequency ablation of accessory pathways in children and congenital heart disease patients: impact of a nonfluoroscopic navigation system. *Pacing Clin Electrophysiol* 2011; 34: 1288-396.
15. Tuzcu V. Significant reduction of fluoroscopy in pediatric catheter ablation procedures: Long-term experience from a single center. *Pacing Clin Electrophysiol* 2012; 35: 1067-73. [\[CrossRef\]](#)

16. Gist K, Tigges D, Smith G, Clark J. Learning curve for zero fluoroscopy catheter ablation of AVNRT: Early versus late experience. *Pacing Clin Electrophysiol* 2011; 34: 264-8. [\[CrossRef\]](#)
17. Miyake CY, Mah DY, Atallah J, Oikle HP, Melgar ML, Alexander ME, et al. Nonfluoroscopic imaging systems reduce radiation exposure in children undergoing ablation of supraventricular tachycardia. *Heart Rhythm* 2011; 8: 519-25. [\[CrossRef\]](#)
18. Silver ES, Silva JN, Ceresnak SR, Chiesa NA, Rhee EK, Dubin AM, et al. Cryoablation with an 8-mm-tip catheter for pediatric atrioventricular nodal reentrant tachycardia is safe and efficacious with a low incidence of recurrence. *Pacing Clin Electrophysiol* 2010; 33: 681-6. [\[CrossRef\]](#)
19. Karadeniz C, Akdeniz C, Turan O, Tuzcu V. Cryoablation of septal accessory pathways in children: midterm results. *Pacing Clin Electrophysiol* 2014; 37: 1095-9. [\[CrossRef\]](#)
20. Parvez B, Pathak V, Schubert CM, Wood M. Comparison of lesion sizes produced by cryoablation and open irrigation radiofrequency ablation catheters. *J Cardiovasc Electrophysiol* 2008; 19: 528-34. [\[CrossRef\]](#)
21. Law IH, Fischbach PS, LeRoy S, Lloyd TR, Rocchini AP, Dick M. Access to the left atrium for delivery of radiofrequency ablation in young patients: retrograde aortic vs transseptal approach. *Pediatr Cardiol* 2001; 22: 204-9. [\[CrossRef\]](#)
22. von Alvensleben JC, Dick M 2nd, Bradley DJ, LaPage MJ. Transseptal access in pediatric and congenital electrophysiology procedures: defining risk. *J Interv Card Electrophysiol* 2014; 41: 273-7.