








Emergent hybrid treatment strategy in a patient with impending rupture of descending aorta aneurysm, including an aberrant right subclavian artery orifice: A rare case report

 Habib Çakır,  Volkan Çakır*,  İsmail Yüreklı,  Utkan Tunca,  Yaşar Gökıurt,  Köksal Dönmez,  Güleycan Erbil¹,  Mert Kestelli,  Ali Gürbüz

Departments of Cardiovascular Surgery, and *Interventional Radiology, Katip Çelebi University, Atatürk Training and Research Hospital; İzmir-Turkey

¹Medical Student, Faculty of Medicine, İzmir Katip Çelebi University, İzmir-Turkey

Introduction

In the treatment of elderly and high-risk patients with a descending aortic aneurysm, the hybrid approach emerges as a good alternative (1). In the cases of descending aortic aneurysm ruptures, the mortality and morbidity rates of the conventional surgery are high. Operation periods in this patient group are significantly reduced with the hybrid approach. For these reasons, to avoid conventional surgery in cases where there is no proper neck anatomy (especially proximal descending aortic aneurysm rupture), endovascular procedures are performed by providing an adequate neck after debranching of the aortic arch. Debranching can be performed with anatomic or extra-anatomic bypass methods (2).

In this study, we aimed to present the case of a 70-year-old male patient with an aberrant right subclavian artery (SA) and impending descending aortic aneurysm rupture, including an aberrant right SA orifice treated at a hybrid operation theatre with right external carotid artery (ECA)–right SA bypass, left ECA–left SA bypass, and thoracic endovascular aortic repair (TEVAR).

Case Report

A 70-year-old male patient was referred to the emergency department with a sudden-onset back pain complaint that lasted for approximately 3 days. His medical history included hypertension. Contrast-enhanced computed tomography (CT) in the arterial phase revealed the aneurysm's origin, the aortic arch and branches in each of the three planes, and the structure of the aneurysm, its diameter, segment length, and relationship of the aneurysm with the supraaortic structures. CT from another medical center detected an impending aneurysm rupture in the descending aorta with a diameter of 64 mm (Fig. 1). Both carotid arteries originated

from a common trunk from the aortic arch, and there was no aneurysmatic dilatation in the aortic arch. Ascending aorta aneurysm, reaching 60 mm in diameter at the largest, was detected. Aortic regurgitation was not detected in transthoracic echocardiography. Aortic arch was not aneurysmatic. The patient was evaluated in cardiovascular surgery and invasive radiology joint council. Due to the character of the back pain, only an emergent surgical intervention to impending aneurysm rupture at descending aorta was decided. Endovascular repair to the descending aortic aneurysm was planned. The occlusion of the left SA orifice was planned after it was considered that there was not enough neck to position the proximal stent graft. The right SA was aberrant, and the orifice of the right aberrant SA was within the aneurysm sac that was going to be occluded. It was decided to bypass both SAs. Since the patient had ascending aortic aneurysm, and this aneurysm had an elective surgery indication, an extra-anatomic bypass was de-

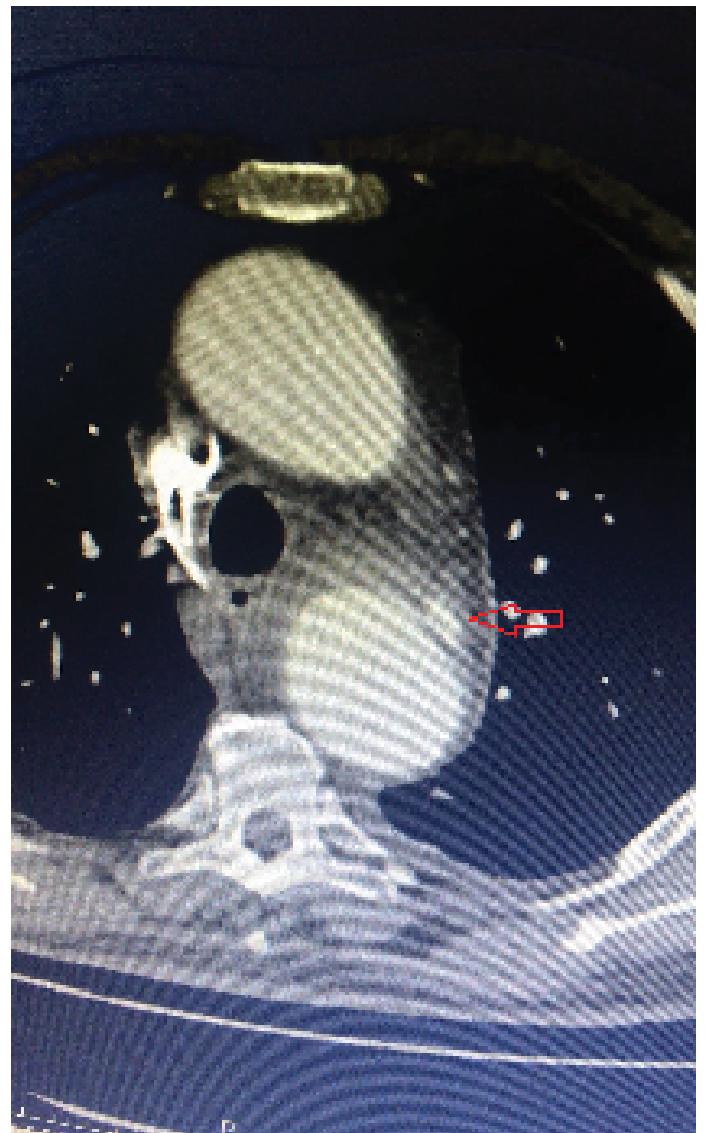


Figure 1. Preoperative CT image of impending rupture

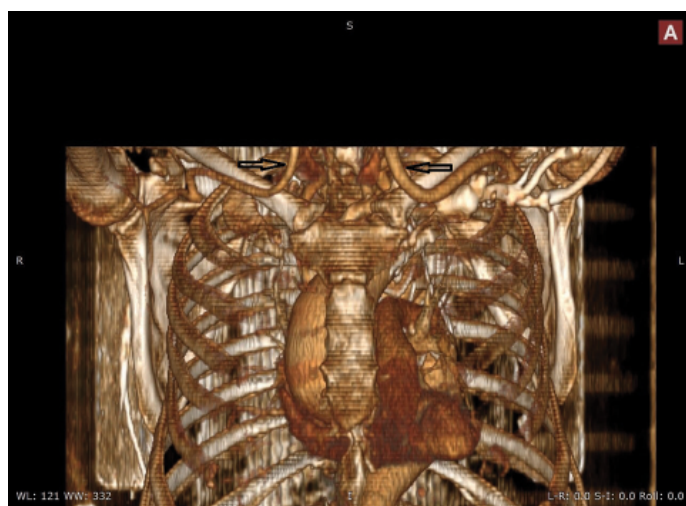


Figure 2. Postoperative CT angiographic view (arrows indicate extra-anatomic bypass grafts)

cided instead of median sternotomy. Because of the widespread aneurysm in the patient and the associated risk of atherosclerosis and the condition of the Willis polygon are unknown, it was decided to use ECA for the donor artery if calibration was appropriate to avoid brain ischemia. To avoid arm ischemia, it was decided to perform bypass operations first.

One of the operating rooms at the cardiac surgery clinic in our hospital is specifically designed for diagnostic and interventional procedures using radiation. We have a C-armed scopy and carbon surgery table in this room. Hybrid interventions or operations that may require a multidisciplinary hybrid approach are performed in this room. Every day, we have common councils of cardiovascular surgery and interventional radiology departments. Interventional teams are created if necessary. We decided to perform hybrid surgery as an interventional team. The patient underwent emergent surgery by both cardiovascular surgery and interventional radiology clinics simultaneously at the hybrid operating theater. Under general anesthesia, both ECAs were explored and taken under control. Both ECAs were found to have a good calibration. Both SA were explored via infraclavicular approach and taken under control. The right ECA–right SA bypass procedure was performed with a 6-mm-ring PTFE graft (over the clavicle) by tunneling under the skin. The left ECA–left SA bypass procedure was performed with an 8-mm-ring PTFE (over the clavicle) graft by tunneling under the skin. The right common femoral artery was explored and taken under control. A 7F sheath was placed. The TEVAR procedure was performed to the descending aortic aneurysm with a Medtronic Valiant stent graft (46x46x150 mm). The aortic Zone 2 was selected as the proximal landing zone of the stent graft. Due to the position of the aberrant right RA in the descending aortic aneurysm, the right SA was occluded proximally to the anastomosis to avoid a Type 2 endoleak. No intervention was performed to the right vertebral artery. After the procedure, control angiography showed no sign of endoleak, and anastomosis with the PTFE grafts was found to be open (Video 1).

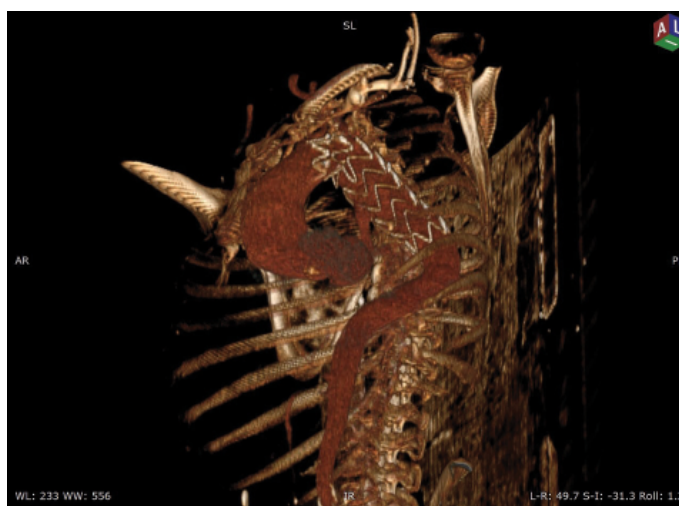

Figure 3. Postoperative CT angiographic view showing the stent graft within the descending aorta

The patient was transferred to the intensive care unit with respiratory support. Postoperative pulses of both the radial and ulnar arteries were palpable. There was no major or minor neurological complication. Routine follow-ups were stable. We decided to perform surgery for the ascending aortic aneurysm in a further session. The patient was discharged without any problems on the postoperative 7th day. CT angiography was performed on the postoperative 30th day. There was not any evidence of endoleak in control CT angiography (Fig. 2, 3).

Discussion

Perioperative mortality was 46% in the conventional surgical treatment and 28% in the TEVAR treatment of ruptured isolated descending aortic aneurysms (3). Due to this superiority of endovascular treatment methods in the descending aortic aneurysms, they became the treatment of choice. In addition, an increase in technology and intervention experience that has developed in recent years has emerged as an important factor in this preference. If there is not enough neck in the treatment of proximal descending aortic aneurysms, endovascular methods are technically more challenging. Having enough neck is a very important factor to avoid re-intervention and endoleak. Because of the superiority of endovascular treatment in the early period, partial or total debranching is performed on the aortic arch to provide adequate landing zone in these cases (2). Subsequently, endovascular procedures are performed after sufficient neck has been obtained. We chose the endovascular method for treatment in our case because of the impending rupture and the high risk of conventional surgery. The aneurysm began exactly at Zone 3. We planned the proximal landing zone of the stent graft as Zone 2, because in the TEVAR procedures, at least 2 cm of the non-aneurysmatic intact aorta should be sealed both proximally and distally. The right SA would be occluded, even in Zone 2, because of the presence of aberrant right SA and orifice of the aberrant right

SA emerging from the aneurysmatic segment of the descending aorta. For this reason, both subclavian arteries had to be bypassed.

The most common anatomic variation of the supraaortic trunk is the aberrant right SA. Surgical indications for aberrant right SA are the aneurysm rupture risk, aneurysm compression symptoms, and embolic complications (4). There were no aneurysms and embolic complications in the aberrant right SA in our case. When the literature is searched, we could not find any case of descending aortic aneurysms including the aberrant right SA orifice thus far. Also, we performed an aberrant right SA ligation to avoid Type 2 endoleak when repairing a descending aortic aneurysm.

Anatomic or extra-anatomic bypass can be used when performing total or partial debranching of the aorta. The long-term patency of the extra-anatomic bypass when performing aortic arch debranching is good (2). Anatomic bypass was not performed for debranching because of the aneurysm in ascending aorta. Bilateral external carotid arteries were used for an extra-anatomic bypass. But in general, the common carotid artery is preferred for inflow of the carotid-subclavian bypass. Shimura et al. (4) performed a left ECA-left SA bypass in 15 patients who underwent TEVAR. The authors reported good patency of the graft during the follow-up period and had only one recurrent left laryngeal nerve palsy. We decided to use external carotid arteries to avoid possible neurological complications because of the presence of an aberrant right SA and aortic arch variation, and the condition of the Willis polygon was unknown and not assessed (due to emergency operation planning). Bilateral external carotid arteries were used as inflow due to the appropriate size of the external carotid artery. No major or minor neurological complications occurred in the postoperative period.

Endoleak is one of the most common complications of endovascular aneurysm repair procedures. This situation may be due to structural or progressive nature of an aneurysm. Despite, reporting patient as event-free may be early, and a CT follow-up on the 30th day did not reveal any problems.

Conclusion

In conclusion, because of the high mortality and morbidity rates with the conventional surgery, the TEVAR treatment can be conducted by performing a partial debranching operation to obtain sufficient neck, if there is not sufficient neck for endovascular treatment in proximal impending ruptures of the descending aortic aneurysm. An anatomic or extra-anatomic bypass can be used when performing partial debranching of the aorta. External carotid artery can be used instead of the common carotid artery as an inflow to avoid neurological complications (if the ECA diameter is appropriate).

References

1. Shuto T, Wada T, Miyamoto S, Kamei N, Hongo N, Mori H. Ten-year experience of the thoraco-abdominal aortic aneurysm treatment using a hybrid thoracic endovascular aortic repair. *Interact Cardiovasc Thorac Surg* 2018; 26: 951-6. [\[CrossRef\]](#)
2. Martin G, Riga C, Gibbs R, Jenkins M, Hamady M, Bicknell C. Short- and Long-term Results of Hybrid Arch and Proximal Descending Thoracic Aortic Repair: A Benchmark for New Technologies. *J Endovasc Ther* 2016; 23: 783-90. [\[CrossRef\]](#)
3. Goodney PP, Travis L, Lucas FL, Fillinger MF, Goodman DC, Cronenwett JL, et al. Survival after open versus endovascular thoracic aortic aneurysm repair in an observational study of the Medicare population. *Circulation* 2011; 124: 2661-9. [\[CrossRef\]](#)
4. Shimura S, Yamaguchi M, Cho Y, Aki A, Furuya H, Ueda T. External carotid-to-subclavian artery bypass in stent grafting of thoracic aorta. *Asian Cardiovasc Thorac Ann* 2013; 21: 546-50. [\[CrossRef\]](#)

Video 1. Control angiography after the procedure.

Address for Correspondence: Dr. Habib Çakır,

İzmir Katip Çelebi Üniversitesi,
Atatürk Eğitim ve Araştırma Hastanesi,
Kalp ve Damar Cerrahisi Kliniği,
İzmir-Türkiye

Phone: +90 532 485 90 51

E-mail: habibcakir35@hotmail.com

©Copyright 2018 by Turkish Society of Cardiology - Available online
at www.anatoljcardiol.com

DOI:10.14744/AnatolJCardiol.2018.00525



Concomitant left main coronary artery and prosthetic mitral valve thrombosis treatment

İD Ayhan Olcay

Department of Cardiology, Faculty of Medicine, İstanbul Aydın University; İstanbul-Turkey

Introduction

Significant left main coronary artery (LMCA) thrombosis has a 40%–80% mortality, and the treatment strategy is determined from experience in LMCA stenosis in nonacute cases (1). Coronary revascularization guidelines lack clear Class I suggestion for the management of prosthetic valve thrombosis owing to the lack of randomized trials and leave the choice of treatment to physicians (2). Here we describe a treatment approach used in a patient with combined LMCA thrombosis and PVT.

Case Report

A 41-year-old woman with irregular warfarin use and mechanical mitral valve replacement performed 2 years previously

1. Shuto T, Wada T, Miyamoto S, Kamei N, Hongo N, Mori H. Ten-year experience of the thoraco-abdominal aortic aneurysm treatment us-