

## Thrombotic Microangiopathy with Complement Factor H Gene Mutations Unassociated with Atypical Hemolytic Uremic Syndrome

*Atipik Hemolitik Üremik Sendrom ile İlişkili Olmayan Kompleman Faktör H Gen Mutasyonları Gösteren Trombotik Mikroanjyopati*

To the Editor,

Atypical hemolytic uremic syndrome (aHUS) is a rare multigenic disorder characterized by thrombotic microangiopathy (TMA). Among the genes that are associated with aHUS, mutations in the complement factor H (CFH) gene are the most common genetic cause of the disease. Several specific gene mutations have been identified in patients with aHUS [1,2,3].

A 5-year-old boy was admitted to our hospital with fatigue. Physical examination revealed pallor and hepatomegaly. His blood pressure was within the normal range. A blood smear showed hemolysis with 10% schistocytes and polychromasia. He had anemia with 5.5 g/dL hemoglobin level and 14.6% reticulocyte level. He had also thrombocytopenia ( $48,000/\text{mm}^3$ ) and elevated lactate dehydrogenase (LDH) as 1066 U/L. A direct Coombs test was negative. The other blood parameters of the patient were as follows: haptoglobin 5 mg/dL (reference range: 41-165 mg/dL), C3 122 mg/dL (reference range: 79-152 mg/dL), creatinine level 0.5 mg/dL, blood urea nitrogen 12 mg/dL, and indirect bilirubin 7 mg/dL. Urine analysis was normal. On the second day of admission, the patient's thrombocyte count dropped to  $38,000/\text{mm}^3$ , his LDH level remained elevated, and schistocytes were still present on his peripheral blood smear. As for the blood smear and other TMA symptoms, first plasmapheresis was started, which lasted 20 weeks. Then treatment was continued with 600 mg of eculizumab weekly for the first three weeks and followed by once every 2 weeks (total 11 doses). Although the patient had TMA symptoms he didn't have renal insufficiency. Also ADAMTS-13 activity was 48% (reference range: 40%-130%) and ADAMTS-13 antibody was negative.

Four months after stopping eculizumab, the patient's levels of hemoglobin, thrombocytes, reticulocytes, haptoglobin and LDH were 11 g/dL,  $150,000/\text{mm}^3$ , 0.87%, 46.4 mg/dL (reference range: 41-165 mg/dL) and 385 U/L, respectively. Informed consent was obtained for genetic testing and publishing the patient's data from his parents.

DNA sequencing analysis of the patient revealed a homozygous *p.His402Tyr* mutation due to a p.1204 C>T change in exon 9, a homozygous *p.Ala307Ala* mutation due to a p.921A>C change in exon 7 and a heterozygous

*p.Ala473Ala* mutation due to a p.1419G>A change in exon 10 of the *CFH* gene (Figure 1).

*CFH* gene mutations are the most commonly observed genetic changes in patients with aHUS and they are responsible in 20%-30% of the patients [1,2,3]. Eighty-seven *CFH* gene mutations associated with aHUS have been described to date [4,5]. The *CFH* gene mutation that we identified in our case has been associated with membranoproliferative glomerulonephritis (MPGN) and age-related macular degeneration (AMD) [6,7,8]. The location of the *p.His402Tyr* mutation in the functional domain of the protein suggests that it might have a pathogenic effect in patients with aHUS [5].

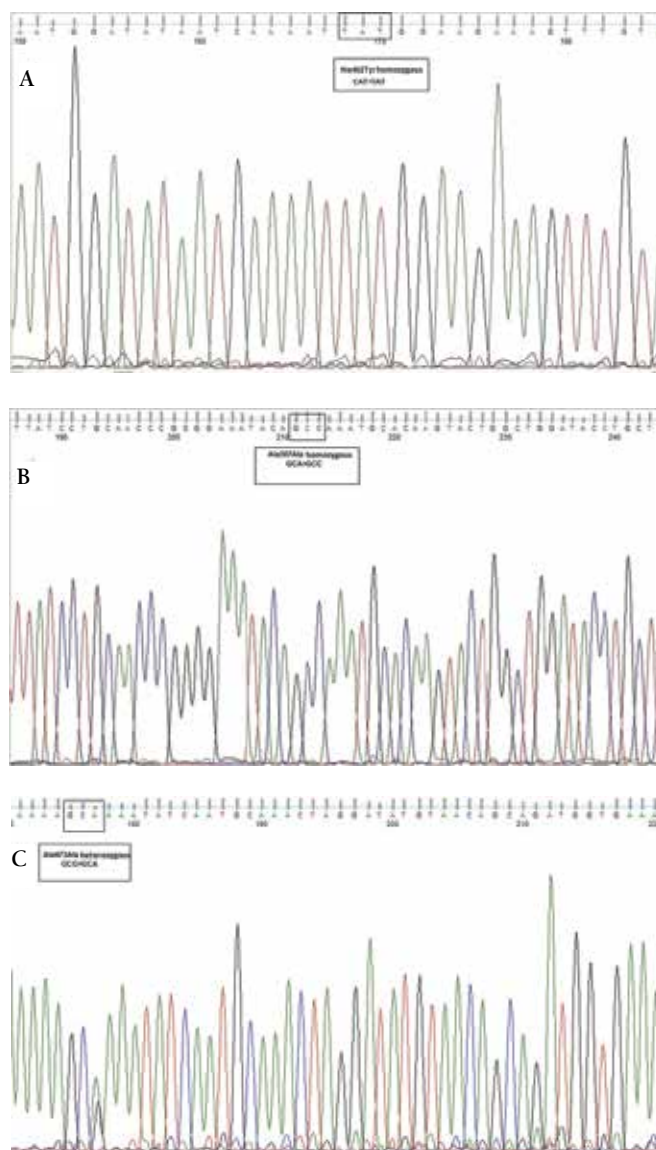


Figure 1. Sequencing data of complement factor H gene mutations of patient. A) Homozygous *p.His402Tyr* mutation. B) Homozygous *p.Ala307Ala* mutation. C) Heterozygous *p.Ala473Ala* mutation.

In conclusion *CFH* gene analysis was performed to confirm whether the patient had aHUS or not. However, we have found *CFH* gene mutations that are not specific for aHUS. Epigenetic factors might have triggered the patient's phenotype. Also *p.His402Tyr* mutation may cause TMA with a milder clinic feature than that of other aHUS specific *CFH* gene mutations.

#### Conflict of Interest Statement

The authors of this paper have no conflicts of interest, including specific financial interests, relationships, and/or affiliations relevant to the subject matter or materials included.

**Key Words:** Thrombotic microangiopathy, Eculizumab, aHUS, *CFH* gene

**Anahtar Sözcükler:** Trombotik mikroangiopati, Eculizumab, aHUS, *CFH* geni

Yeşim Oymak<sup>1</sup>, Tuba Hilkey Karapınar<sup>1</sup>, Yılmaz Ay<sup>1</sup>, Esin Özcan<sup>1</sup>, Neryal Müminoğlu<sup>1</sup>, Sultan Aydın Köker<sup>1</sup>, Ersin Töret<sup>1</sup>, Afif Berdeli<sup>2</sup>, Erkin Serdaroğlu<sup>3</sup>, Canan Vergin<sup>1</sup>

<sup>1</sup>Dr. Behçet Uz Children's Hospital, Clinic of Hematology, İzmir, Turkey

<sup>2</sup>Ege University Faculty of Medicine, Department of Genetics, İzmir, Turkey

<sup>3</sup>Dr. Behçet Uz Children's Hospital, Clinic of Nephrology, İzmir, Turkey

#### References

- Caprioli J, Noris M, Brioschi S, Pianetti G, Castelletti F, Bettinaglio P, Mele C, Bresin E, Cassis L, Gamba S, Porrati F, Bucchioni S, Monteferrante G, Fang CJ, Liszewski MK, Kavanagh D, Atkinson JP, Remuzzi G; International Registry of Recurrent and Familial HUS/TTP. Genetics of HUS: the impact of MCP, CFH, and IF mutations on clinical presentation, response to treatment, and outcome. *Blood* 2006;108:1267-1279.
- Caprioli J, Bettinaglio P, Zipfel PF, Amadei B, Daina E, Gamba S, Skerka C, Marziliano N, Remuzzi G, Noris M; Italian Registry of Familial and Recurrent HUS/TTP. The molecular basis of familial hemolytic uremic syndrome: mutation analysis of factor H gene reveals a hot spot in short consensus repeat 20. *J Am Soc Nephrol* 2001;12:297-307.
- Noris M, Caprioli J, Bresin E, Mossali C, Pianetti G, Gamba S, Daina E, Fenili C, Castelletti F, Sorosina A, Piras R, Donadelli R, Maranta R, van der Meer I, Conway EM, Zipfel PF, Goodship TH, Remuzzi G. Relative role of genetic complement abnormalities in sporadic and familial aHUS and their impact on clinical phenotype. *Clin J Am Soc Nephrol* 2010; 5:1844-1859.
- Rodriguez E, Rallapalli PM, Osborne AJ, Perkins SJ. New functional and structural insights from updated mutational databases for complement factor H, factor I, membrane cofactor protein and C3. *Biosci Rep* 2014;34:e00146.
- Saunders RE, Abarrategui-Garrido C, Frémeaux-Bacchi V, Goicoechea de Jorge E, Goodship TH, López Trascasa M, Noris M, Ponce Castro IM, Remuzzi G, Rodríguez de Córdoba S, Sánchez-Corral P, Skerka C, Zipfel PF, Perkins SJ. The interactive Factor H-atypical hemolytic uremic syndrome mutation database and website: update and integration of membrane cofactor protein and Factor I mutations with structural models. *Hum Mutat* 2007;28:222-234.
- Abrera-Abeleda MA, Nishimura C, Smith JL, Sethi S, McRae JL, Murphy BF, Silvestri G, Skerka C, Józsi M, Zipfel PF, Hageman GS, Smith RJ. Variations in the complement regulatory genes factor H (CFH) and factor H related 5 (CFHR5) are associated with membranoproliferative glomerulonephritis type II (dense deposit disease). *J Med Genet* 2006;43:582-589.
- Hageman GS, Anderson DH, Johnson LV, Hancox LS, Taiber AJ, Hardisty LI, Hageman JL, Stockman HA, Borchardt JD, Gehrs KM, Smith RJ, Silvestri G, Russell SR, Klaver CC, Barbazetto I, Chang S, Yannuzzi LA, Barile GR, Merriam JC, Smith RT, Olsh AK, Bergeron J, Zernant J, Merriam JE, Gold B, Dean M, Allikmets R. A common haplotype in the complement regulatory gene factor H (HF1/CFH) predisposes individuals to age-related macular degeneration. *Proc Natl Acad Sci USA* 2005;102:7227-7232.
- Haines JL, Hauser MA, Schmidt S, Scott WK, Olson LM, Gallins P, Spencer KL, Kwan SY, Noureddine M, Gilbert JR, Schetz-Boutaud N, Agarwal A, Postel EA, Pericak-Vance MA. Complement factor H variant increases the risk of age-related macular degeneration. *Science* 2005;308:419-421.

**Address for Correspondence:** Yeşim OYMAK, M.D.,  
Dr. Behçet Uz Children's Hospital, Clinic of Hematology, İzmir, Turkey  
Phone: +90 532 355 42 28 E-mail: yesimoymak@hotmail.com

Received/Geliş tarihi: February 17, 2015

Accepted/Kabul tarihi: March 18, 2015

DOI: 10.4274/tjh.2015.0084



## Rapidly Growing Thyroid Mass: An Unusual Case of Acute Lymphoblastic Leukemia

*Hızlı Büyüyen Tiroid Kitlesi: Sıradışı Bir Akut Lenfoblastik Lösemi Olgusu*

#### To the Editor,

Extramedullary presentations of acute lymphoblastic leukemia (ALL) in the central nervous system (CNS), lymph nodes, gonads, spleen, and liver can also be observed. Thyroid infiltration of ALL is very rare. A 53-year-old woman was admitted to the endocrinology outpatient clinic with a lump in the throat, which increased in size over a week. Her medical and family history were nonspecific. Except sensitive and painful thyroid, physical examination findings were normal. Complete blood count values were as follows: